



Imaging Sciences Interesting Cases

CASE 109

Corey Sides, MD

CLINICAL PRESENTATION: A 12-year-old male presented with non-exertional chest pain and tightness. No history of trauma or precipitating event.

IMAGING FINDINGS: Sagittal MRI angiogram [Fig. 1] and volume rendered image [Fig. 2- large white arrow] demonstrate significant narrowing (7mm) of the descending thoracic aorta beyond the origin of the left subclavian artery, at the level of the aortic isthmus. Two and three chamber FIESTA [Figs. 3 & 4] demonstrate a normal left ventricle and a left ventricular outflow tract.

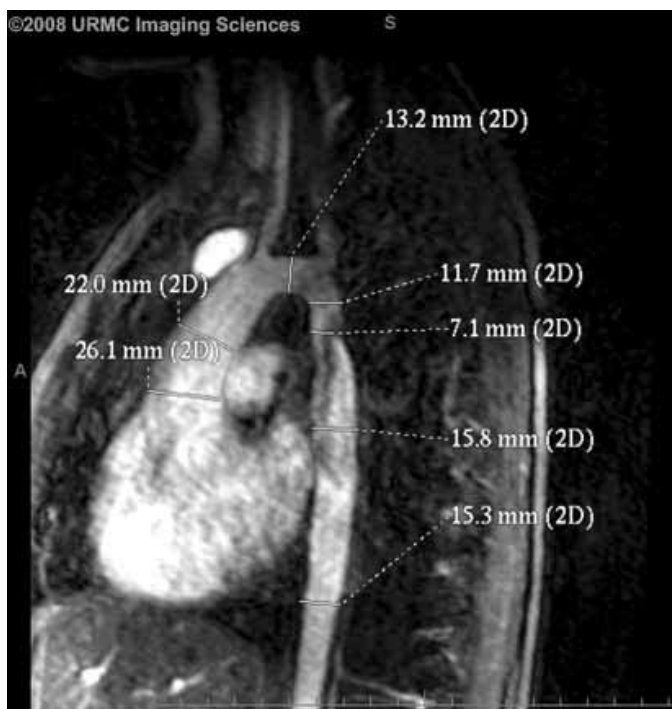


Figure 1. Sagittal MR angiogram.

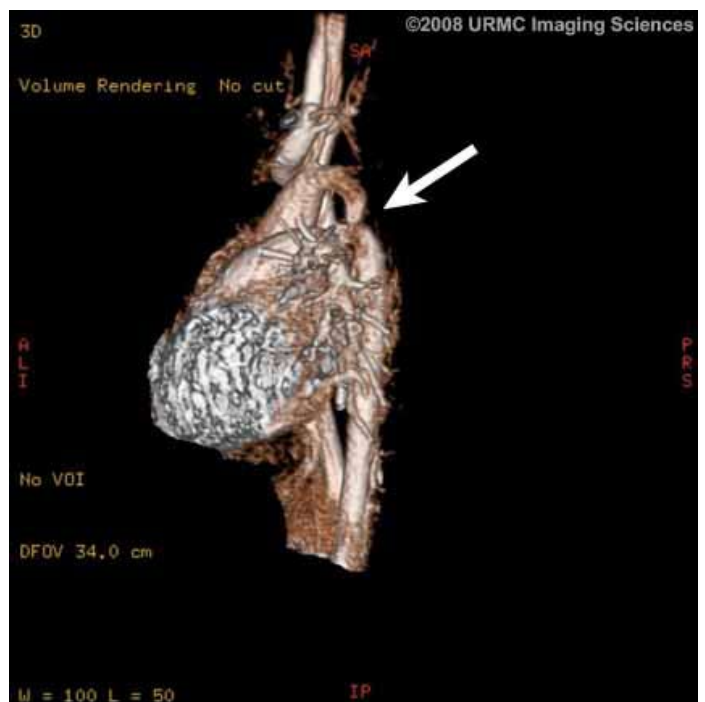


Figure 2. Volume rendered image.

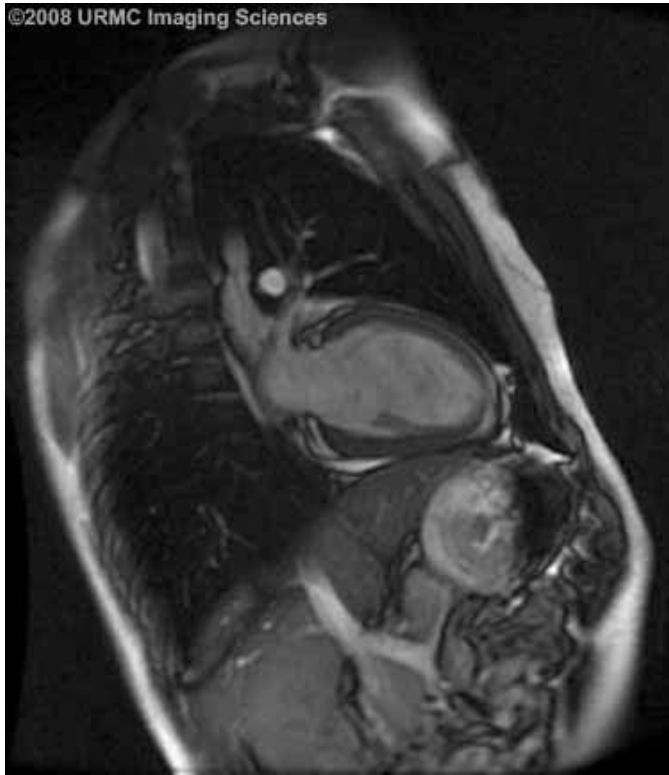


Figure 3. Two chamber FIESTA.

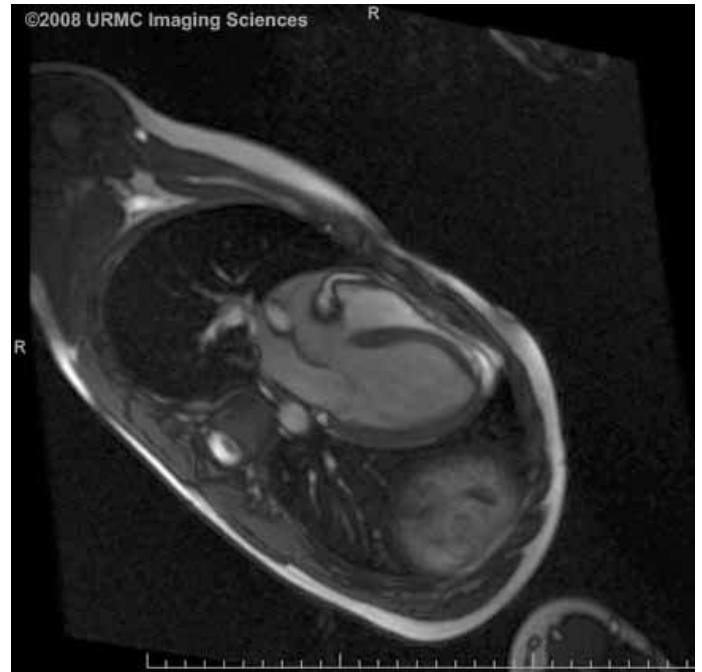


Figure 4. Three chamber FIESTA.

DIAGNOSIS: Aortic Coarctation

DISCUSSION: Coarctation is an acyanotic congenital heart defect with stenosis of the thoracic aorta and incidence of 1:6000 births. It is categorized as pre-ductal or post-ductal coarctation depending on the relationship with the ductus arteriosus. Post-ductal coarctation is more common than pre-ductal and accounts for approximately 95% of cases.

The diagnosis can be made with several different modalities, including MRI, which can clearly show narrowing of the descending thoracic aorta, with presence of absence of collateral vessels. VENC (velocity encoded) techniques allow for hemodynamic evaluation of the stenosis.

Classically chest x-ray may show rib notching and the “number three sign” of the aortic contour. The diagnosis can also be made using echocardiography, however there may be technical considerations which limit the evaluation. Patients with aortic coarctation may be symptomatic or present with symptoms of chest pain, palpitations, and hypertension.

Treatment is by balloon angioplasty of the stenosis or surgical repair.

REFERENCES:

1. Gaba RC, Carlos RC, Weadock WJ, Reddy GP, Sneider MB, Cascade PN. Cardiovascular MR imaging: technique optimization and detection of disease in clinical practice. Radiographics. 2002 Nov-Dec;22(6):e6. [PubMed]
2. Amparo EG, Higgins CB, Shafton EP. Demonstration of coarctation of the aorta by magnetic resonance imaging. AJR Am J Roentgenol. 1984 Dec;143(6):1192-4. [PubMed]