



UNIVERSITY of
ROCHESTER
MEDICAL CENTER

UNIVERSITY OF ROCHESTER MEDICAL CENTER
DEPARTMENT OF IMAGING SCIENCES

Imaging Sciences Interesting Cases

CASE 149

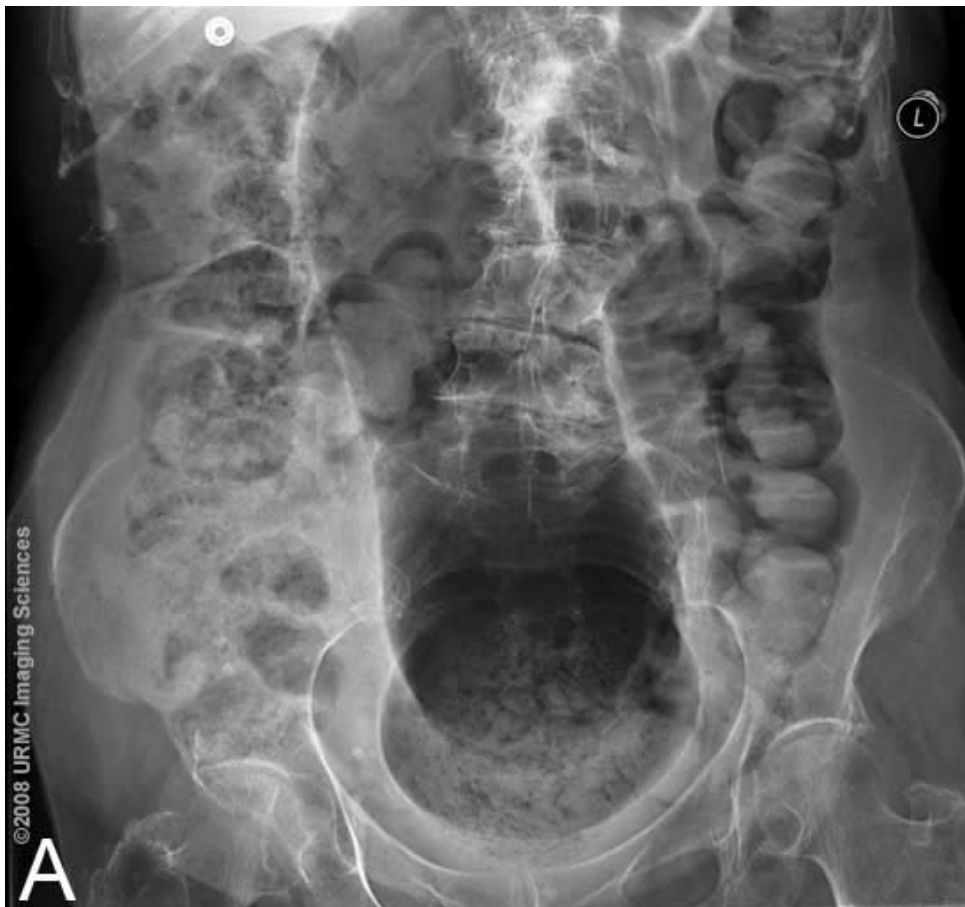B. Keegan Markhardt, MD

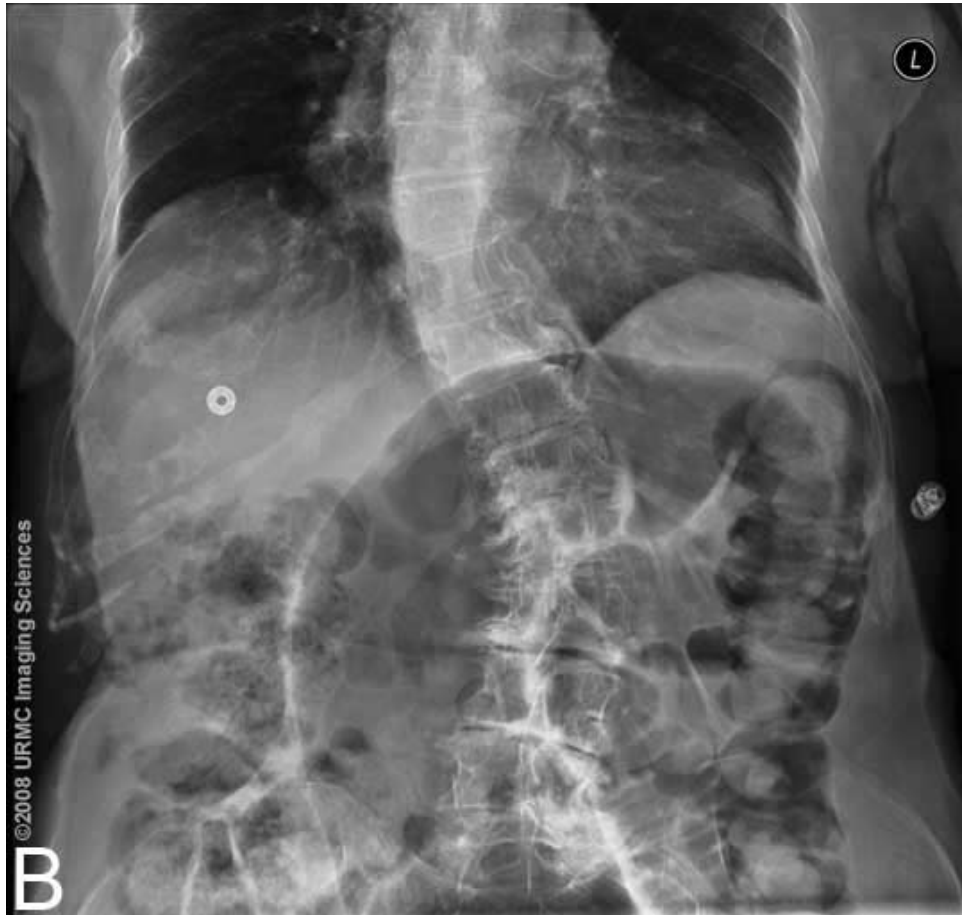
CLINICAL PRESENTATION:

Case 1 is a 90-year-old female, with multiple medical problems including chronic constipation, who presented with abdominal pain and recent development of diarrhea.

Case 2 is a 54-year-old female, with developmental disability and epilepsy, who presented with dyspnea and change in mental status.

IMAGING FINDINGS: See figure legends.





Figures 1A&B (Case 1): Lower abdominal radiographs show a massively dilated and straightened sigmoid colon extending into the upper abdomen with paucity of gas in the rectal region.

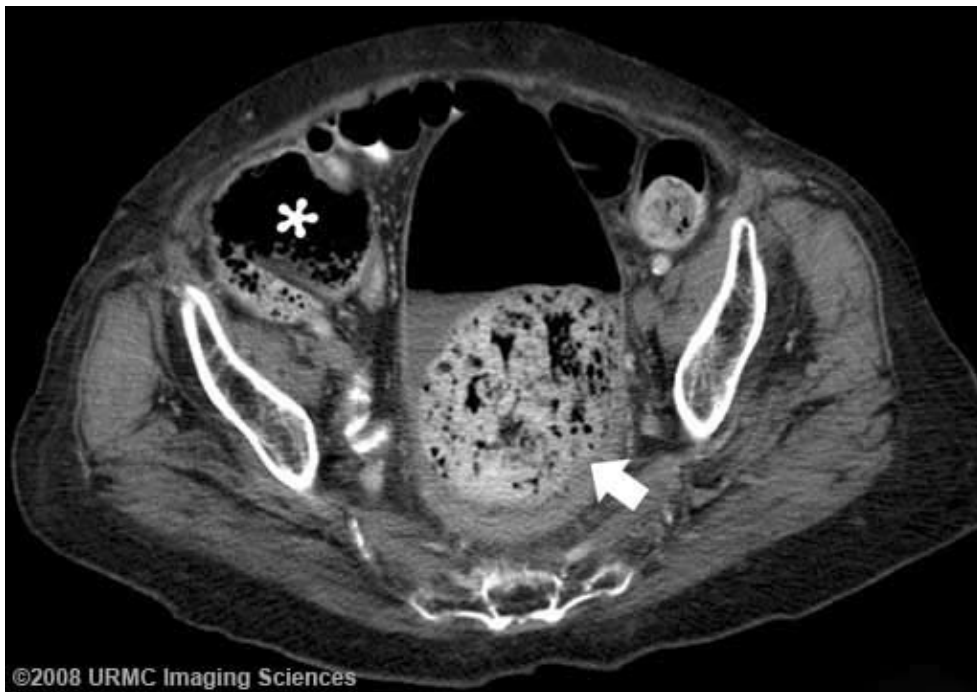

Figure 2 (Case 1): CT at the level of the pelvis demonstrates a large fecolith in the rectosigmoid region (arrow). Note cecum is also dilated consistent with colonic obstruction (asterisk).

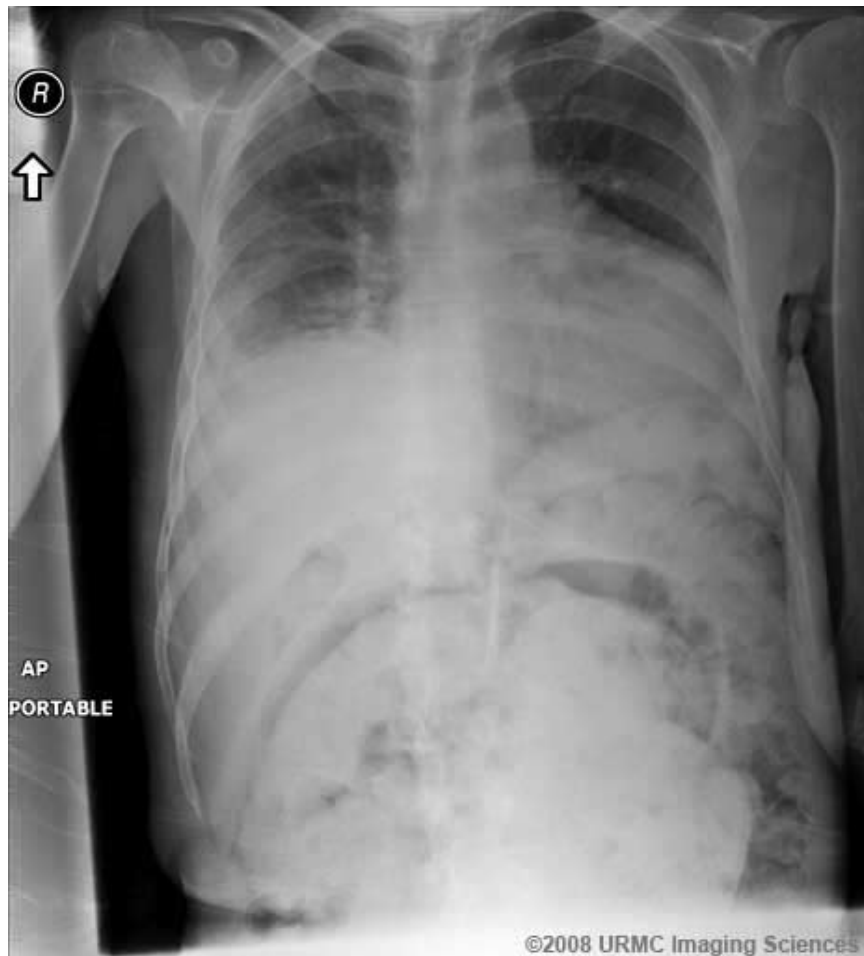

Figure 3 (Case 2): Abdominal radiograph shows a large, high-density mass arising from the pelvis, and possible free air. (Case 2 courtesy of Dr. Brady Huang).

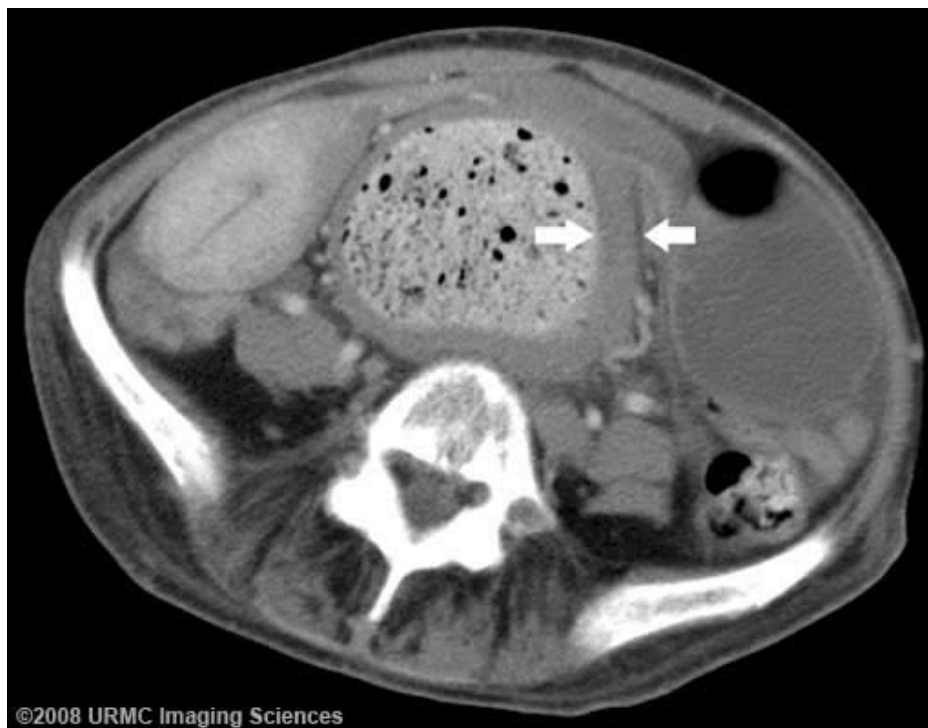

Figure 4 (Case 2): CT at the level of the pelvis demonstrates a large fecolith in the sigmoid colon. There is diffuse colonic wall thickening (arrows), concerning for stercoral colitis.

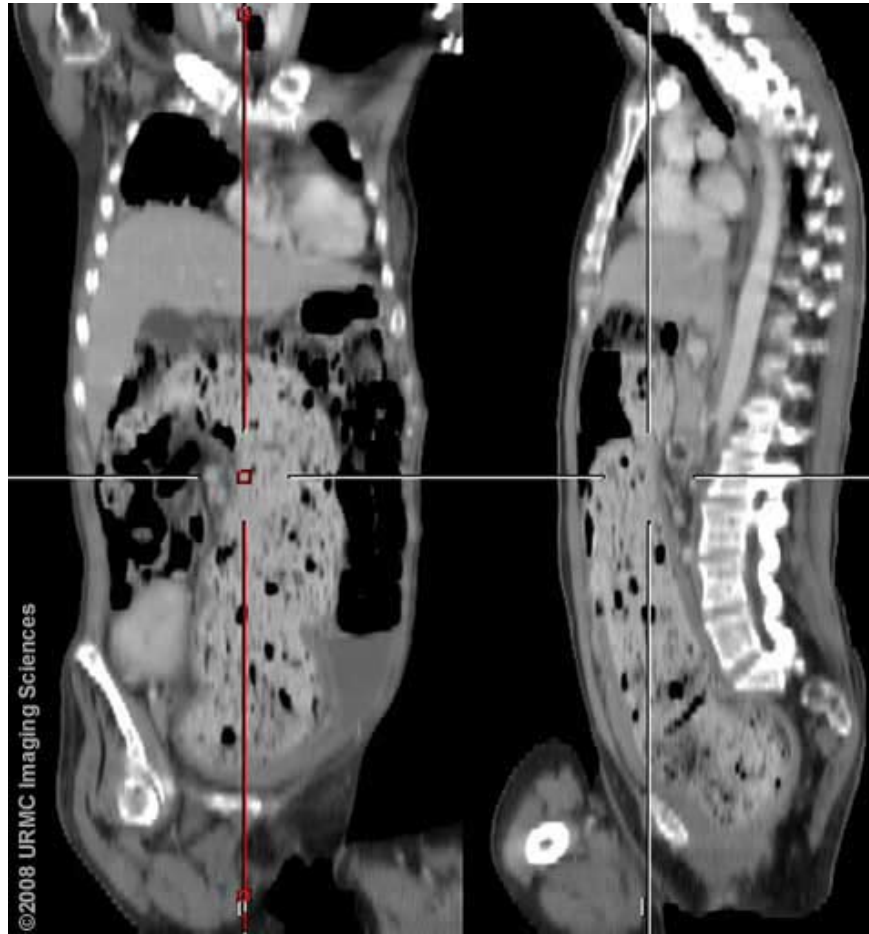

Figure 5 (Case 2): CT coronal and sagittal reformats show the fecal impaction to involve most of the sigmoid colon. Colonic wall thickening is evident.

DIAGNOSIS: Case 1: Fecal Impaction; Case 2: Fecal Impaction with stercoral colitis

DISCUSSION: Fecal impaction is essentially a solid, immobile bulk of stool that cannot be passed. Fecal impaction leading to colonic obstruction is seen primarily in patients with chronic constipation, particularly the elderly and young patients who are neurologically impaired. There is also an association with opiates, tricyclic antidepressants and tranquilizers, which slow bowel transit time. As in our first case, diarrhea may occasionally occur paradoxically as a result of fecal impaction with the overflow of liquid colonic contents around the impacted stool [1].

Complications include the development of stercoral colitis. Stercoral colitis is an inflammatory colitis related to increased intraluminal pressure from impacted fecal material in the colon. If the fecal impaction is not promptly relieved, the condition can lead to colonic ulceration, necrosis, perforation, peritonitis and patient demise.

Radiographs may demonstrate signs of distal colonic obstruction and paucity of gas in the rectum, or a fecolith in the rectum. The dilated, air-filled sigmoid colon seen Case 1 is typical for distal obstruction in the setting of chronic constipation. Small bowel dilatation may also be seen [2].

The CT diagnosis of fecal impaction is usually straightforward. On CT, it is important to evaluate for findings of stercoral colitis. In uncomplicated fecal impaction, the colon is distended and the wall is thin (Case 1). Focal thickening or pericolic fat stranding in a segment of colon that contains fecal impaction suggests ischemia or ulceration (Case 2) [3]. The presence of extraluminal gas or an abscess suggests that perforation has already occurred.

Non-invasive treatments are similar to those for constipation and include increased intake of fluids and

dietary fiber, and physical exercise. However, once fecal impaction occurs, these methods are usually not successful. The mainstay of treatment are enemas to soften the impaction and manual disimpaction. Use of laxatives may be dangerous because of the risk of stercoral perforation. Surgery may be necessary if the bowel becomes totally obstructed.

REFERENCES:

1. Fauci AS, Braunwald E, Isselbacher KJ, et al. (Eds). Harrison's Principles of Internal Medicine. 14th ed. McGraw-Hill 1998; Chapter 41:241.
2. Torigian DA, Levine MS, Rubesin SE, Laufer I. Fecal impaction: a cause of isolated small bowel dilatation on abdominal radiographs. *Eur J Radiol.* 2001 Oct;40(1):45-9. [PubMed]
3. Heffernan C, Pachter HL, Megibow AJ, Macari M. Stercoral colitis leading to fatal peritonitis: CT findings. *AJR Am J Roentgenol.* 2005 Apr;184(4):1189-93. [PubMed]