



UNIVERSITY of
ROCHESTER
MEDICAL CENTER

UNIVERSITY OF ROCHESTER MEDICAL CENTER
DEPARTMENT OF IMAGING SCIENCES

Imaging Sciences Interesting Cases

CASE 369

Richard Gong, MD

CLINICAL PRESENTATION: Patient is a 37-year-old female, with family history of breast cancer in her mother and aunt, who presents with a palpable abnormality in the right breast. Diagnostic mammogram and ultrasound was performed, followed by an ultrasound guided biopsy. Pathology demonstrated poorly differentiated invasive ductal carcinoma. Breast MRI was obtained to assess for occult disease in the left breast and extent of disease in the right breast.

IMAGING FINDINGS: Mammogram shows a non-calcified mass with indistinct borders at the axillary tail of the right breast. Ultrasound shows a hypoechoic, non-calcified mass. MRI shows low T1, intermediate T2, enhancing mass at the right axillary tail consistent with known cancer. No disease is seen in the left breast.

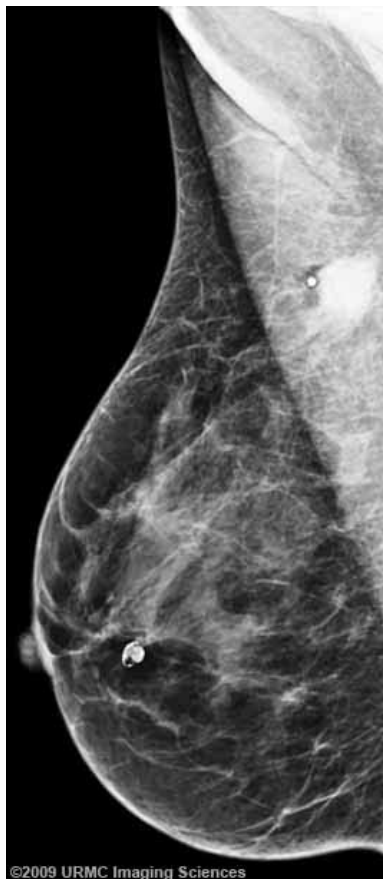


Figure 1. Fig 1. Right MLO mammogram.

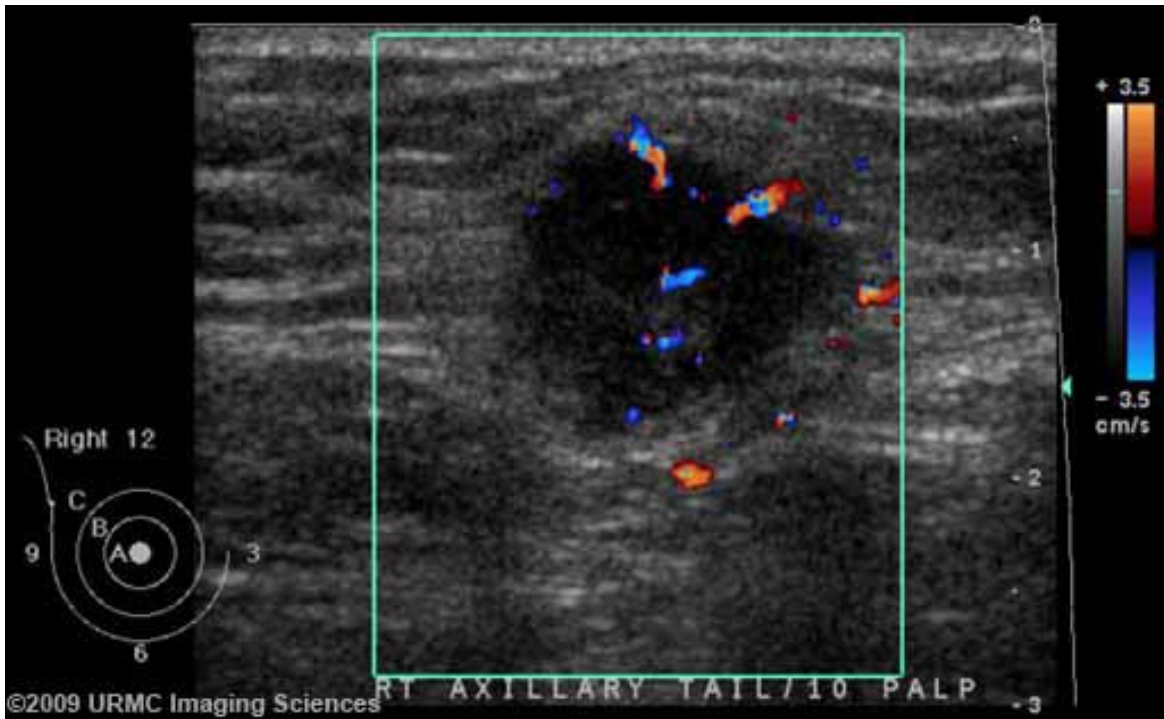


Figure 2. Ultrasound.

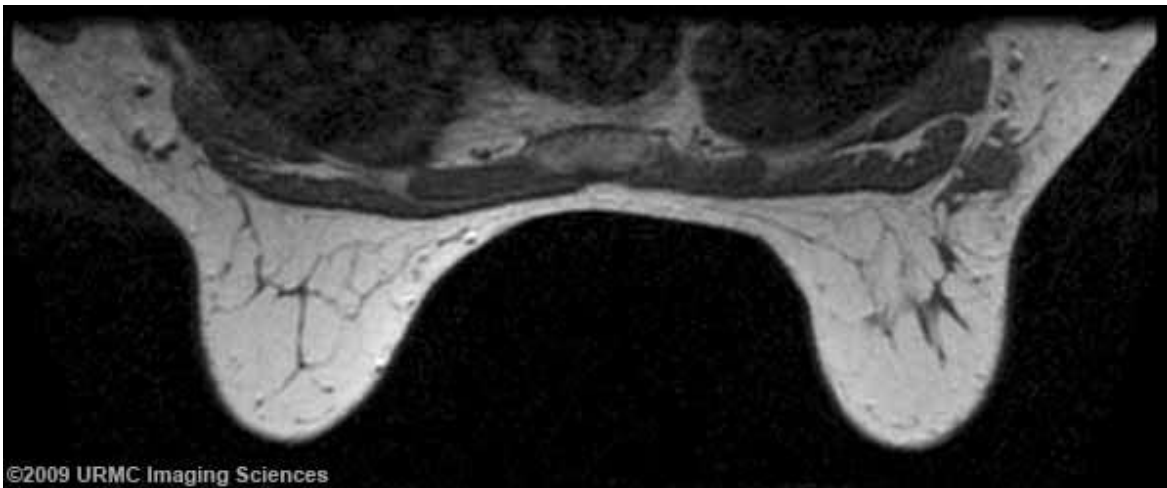


Figure 3. T1 MR.

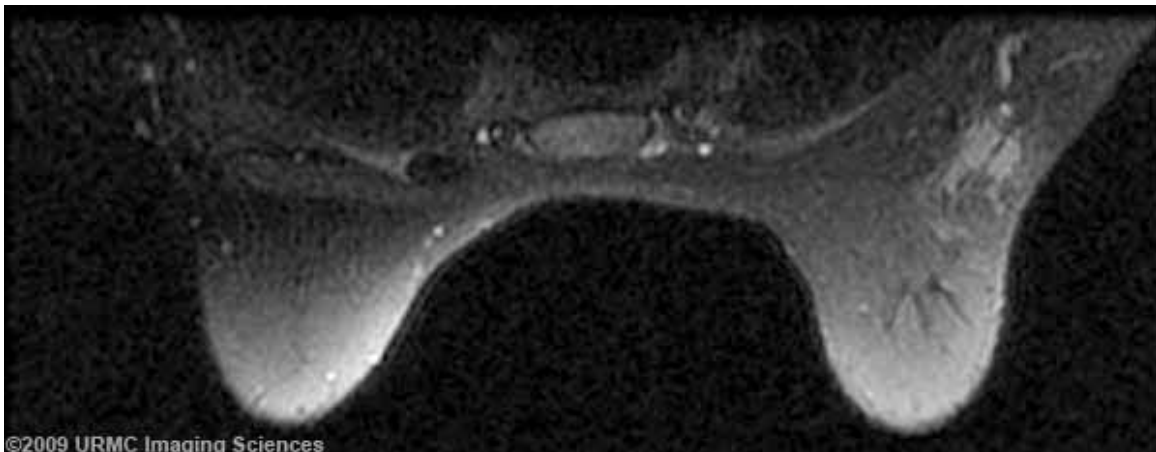


Figure 4. T2 with fat saturation MR.

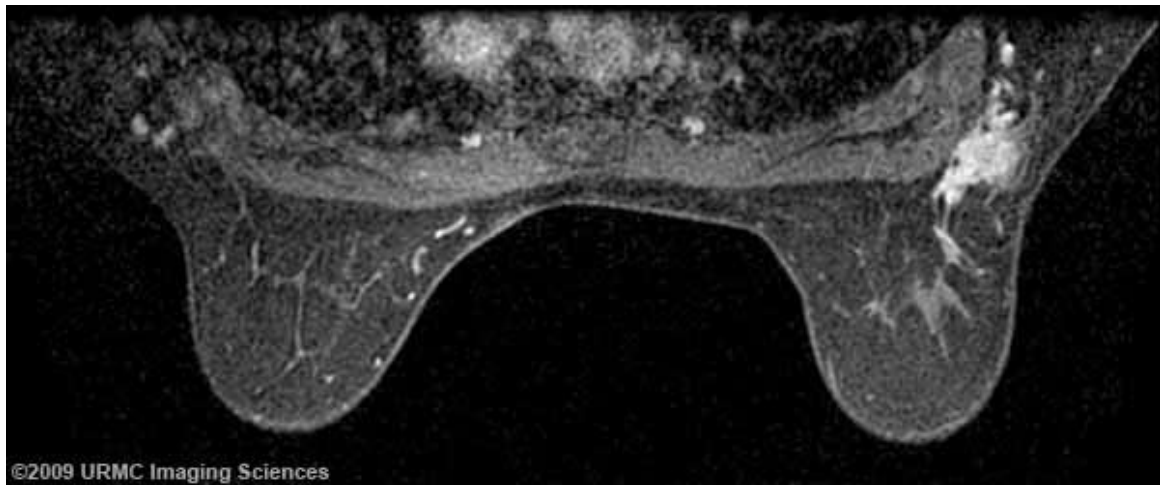


Figure 5. Post-contrast MR.

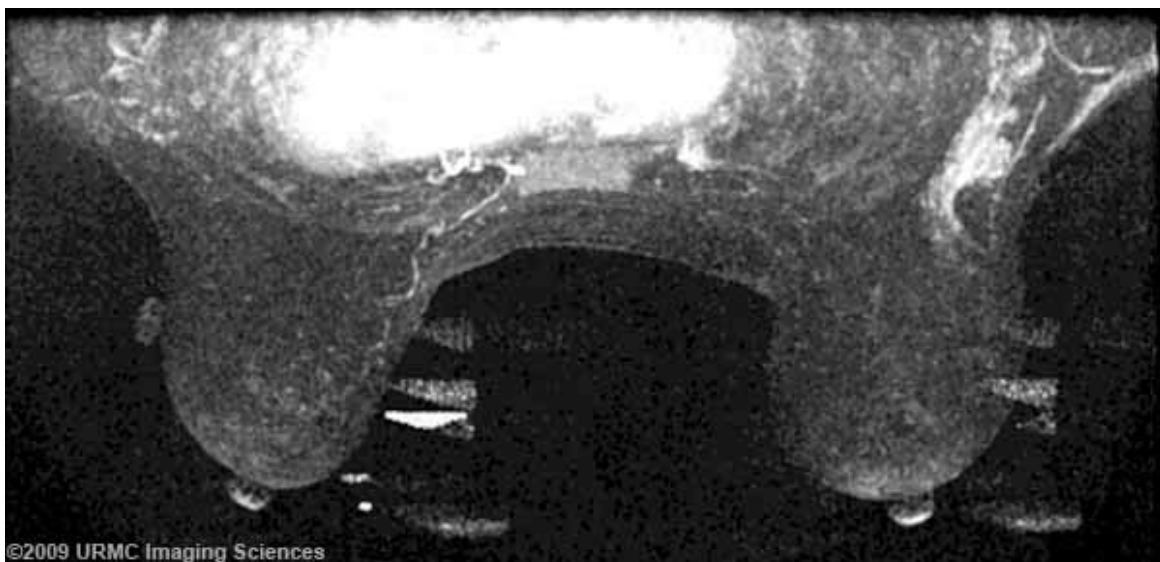


Figure 6. Post-contrast MIP.

DIAGNOSIS: Poor differentiated invasive ductal carcinoma

DISCUSSION: The current indications for Breast MRI according to the ACR practice guidelines can broadly be classified as screening, evaluating extent of disease and additional evaluation of clinical or imaging findings.

Screening of patient with high lifetime risk of breast cancer, more than 20%, may be usehe third screening indication is in patients with breast augmentation.

MRI may also be indicated to evaluate the extent of disease. MRI demonstrates the extent of disease more accurately than mammography or physical examination in many patients. The presence of multifocality and multicentricity in invasive carcinoma and ductal carcinoma in situ and of invasion deep to the fascia may affect treatment planning. After lumpectomy, if the pathologist reports positive or close margins, MRI would be helpful for evaluation of residual disease. MRI can also be used for the monitoring of neoadjuvant chemotherapy.

Breast MRI can also be useful in women with clinical suspicion of recurrent breast cancer in the scar 18 months after surgery and other clinical and imaging findings are inconclusive. When patients have evidence of metastatic disease and a breast primary is suspected, MRI may be useful when there is no mammographic or physical finding of breast cancer. Other uses include characterization of lesions that are inconclusive on mammogram and ultrasound and biopsy cannot be performed. MRI can also be useful in

detection of recurrence in patients with tissue transfer flaps.

Currently MRI is not indicated for screening in the general population with average risk. Although MRI is highly sensitive, it does not have the degree of specificity. Therefore abnormal findings on MRI may or may not be clinically relevant and false positive results should be expected. It should also be noted that patients undergoing breast MRI should still undergo standard mammography.

References:

1. ACR guidelines and Standard Committee. ACR Practice Guideline for the Performance of Contrast-Enhanced Magnetic Resonance Imaging of the Breast (2008). http://www.acr.org/SecondaryMainMenuCategories/quality_safety/guidelines/breast/mri_breast.aspx [PDF]
2. Lehman CD, Gatsonis C, Kuhl CK, et al. MRI evaluation of the contralateral breast in women with recently diagnosed breast cancer. *N Engl J Med.* 2007 Mar 29;356(13):1295-303. PMID: 17392300 [PubMed]