

eTumor Board

Gynecologic Oncology

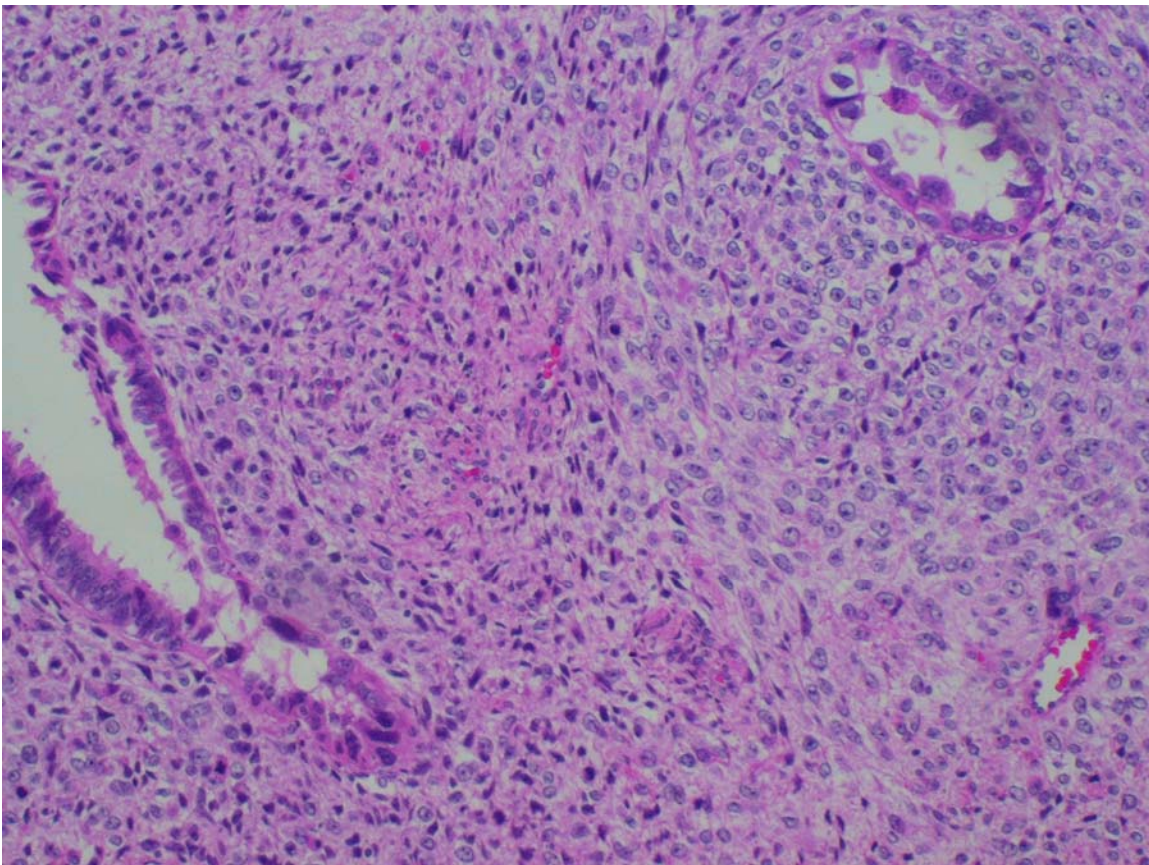
CC: Pelvic pressure and vaginal bleeding

HPI: 78 y/o on HRT presented with pelvic pressure and vaginal bleeding for several weeks

PMH/PSH: Breast cancer, s/p right mastectomy with negative nodes. No chemo or XRT required.

Pathology: See below

Surgery: tah/bsopelvic/aortic lymphadenectomy/omentectomy



Uterine pathology

We are grateful to Wendy Dwyer, MD (Resident in Ob-Gyn), and Cholpady Kamath (Pathology), University of Rochester School of Medicine, for assistance in preparing this case

Questions

1. Which of the following is the histology consistent with? [\(Answer\)](#)
 - a. adenofibroma
 - b. adenosarcoma
 - c. carcinosarcoma
 - d. atypical polypoid adenomyoma
2. This malignancy accounts for what percentage of all uterine malignancies? [\(Answer\)](#)
 - a. <1%
 - b. 1-2%
 - c. 5-7%
 - d. 10-15%
3. What risk factor is associated with this type of cancer? [\(Answer\)](#)
 - a. time of menarche
 - b. time of menopause
 - c. parity
 - d. pelvic irradiation
4. Which of the following does not correlate with a poor prognosis? [\(Answer\)](#)
 - a. cervical involvement
 - b. grade 2 or 3 carcinoma
 - c. presence of stromal heterologous elements
 - d. clear cell histology
5. Randomized trials have demonstrated adjuvant chemotherapy following surgical resection effects survival. [\(Answer\)](#)
 - a. true
 - b. false

Answers

1. **C- Carcinosarcoma.** Also known as malignant mixed mesodermal tumor (MMT). Mixed tumors have an epithelial component as well as a stromal component. In MMT both components are malignant. The epithelial component may be one of several types including endometrioid (most common), serous, clear cell, mucinous, undifferentiated, or squamous. The stromal component is characterized as either homologous or heterologous. Homologous refers to being derived only from uterine tissue such as endometrial stroma or muscle - leiomyosarcoma. Heterologous refers to being derived from organs other than the uterus such as rhabdomyosarcoma, chondrosarcoma, osteosarcoma, or liposarcoma (in order of most common to least common). This patient has an epithelial component of endometrioid type with serous differentiation, and a sarcomatous component with high grade endometrial stromal sarcoma with heterologous elements of rhabdomyosarcoma differentiation.

An adenofibroma has benign epithelial and stromal components. An adenosarcoma has benign epithelial but malignant stromal components. An atypical polypoid adenomyoma has atypical glandular epithelium and benign smooth muscle stroma.

2. **B- 1-2%.** MMT accounts for 1-2% of all uterine malignancies. Uterine sarcomas comprise fewer than 5% of uterine malignancies, with 17 cases per million women annually. MMT is the most common uterine sarcoma.
3. **D- Pelvic irradiation.** A history of pelvic radiation is noted in 5-10% of patients with uterine sarcoma. An increased risk may also be associated with long term adjuvant tamoxifen in breast cancer patients. Parity, time of menopause, or menarche are not associated with increased risk. Most MMTs occur in postmenopausal women with a median age of 65 y/o. About a three-fold increased risk is found among black women compared to white women for uterine sarcoma.
4. **C- Presence of stromal heterologous elements.** The prognosis of uterine sarcomas worsens with the extent of the disease at the time of diagnosis. Significant predictors of metastatic disease at initial surgery in MMT include isthmic or cervical location, vascular or lymphatic space invasion, serous or clear cell histology, and grade 2 or 3 carcinoma. Prognosis also worsens with adnexal spread, lymph node metastases, increased tumor size, and myometrial invasion >50%. There is no significant difference in the prognosis when a malignancy has homologous vs. heterologous elements. The types of elements, grade of stromal components, and mitotic stromal activity are also not associated with the presence or absence of metastases at diagnosis.
5. **B- False.** Adjuvant chemo after surgery has not been proven effective by randomized trials. The value of pelvic irradiation is also not well established. Some nonrandomized trials show improved survival or reduced recurrences following chemo and/or radiation. The most common agents are cisplatin, carboplatin or ifosfamide. Pelvic radiation is associated with improved local control, but no survival benefit has been demonstrated. Standard treatment includes surgery with a TAH, BSO, pelvic and periaortic lymphadenectomy, and resection of all gross tumor.

[Return to Questions](#)

References

- Berek JS, Hacker NF: **Practical Gynecologic Oncology, 3rd Edition.** Williams and Wilkins, Philadelphia, PA. 2000.
- Harlow BL, Weiss NS, Lofton S. The epidemiology of sarcomas of the uterus. *J Natl Cancer Inst* 1986; 76:399.
- Kahanpaa KV, Wahlstrom T, Grohn P, et al.: Sarcomas of the uterus: a Clinicopathologic study of 119 patients. *Obstet Gynecol* 1986; 67:417.
- Platz CE, Benda JA. Female genital tract cancer. *Cancer* 1995; 75:270.
- Meredith RF, Eisert DR, Kaka Z, et al. An excess of uterine sarcoma after pelvic irradiation. *Cancer* 1986; 58:2003.
- Wickerham DL, Fisher B, Wolmark N, et al. Association of tamoxifen and uterine sarcoma. *L Clin Oncol* 2002; 20:2758.
- Wysowski DK, Honig SF, Beitz J. Uterine sarcoma associated with tamoxifen use. *N Engl J Med* 2002; 346:1832.
- Major FJ, Blessing JA, Silverberg SG, et al.: Prognostic factors in early-stage uterine sarcoma: a Gynecologic Oncology Group study. *Cancer* 71 (4, Suppl): 1702-1709, 1993.
- Kohorn EI, Schwartz PE, Chambers JT, et al.: Adjuvant therapy in mixed mullerian tumors of the uterus. *Gynecologic Oncology* 23(2): 212-221, 1986.
- Hornback NB, Omura G, Major FJ. : Observations on the use of adjuvant radiation therapy in patients with stage I and II uterine sarcoma. *International Journal of Radiation Oncology, Biology, Physics* 12(12):2127-2130, 1986.
- Pecorelli SL, EORTC Gynecological Cancer Group: Phase III randomized study of adjuvant pelvic radiotherapy versus observation alone in patients with completely resected, stage I or II, high grade uterine sarcoma (Summary last modified 12/2001), EORTC-55874, clinical trial, closed, 8/10/2001.
- Sutton G, Brunetto VL, Kilgore L, et al.: A phase III trial of ifosfamide with or without cisplatin in carcinosarcoma of the uterus: a Gynecologic Oncology Group study. *Gynecologic Oncology* 79(2):147-153, 2000.
- Thigpen JT, Blessing JA, Beecham J, et al.: Phase II trial of cisplatin as first-line chemotherapy in patients with advanced or recurrent uterine sarcomas: a Gynecologic Oncology Group study. *Journal of Clinical Oncology* 9(11), 1962-1966, 1991.