Diagnostic Challenges with Neurosarcoidosis: Case Report

Jenie George, MD; Tirisham Gyang, MD and Jessica Robb, MD

University of Rochester School of Medicine & Dentistry, Rochester, NY

Background & Objective

- Neuroimaging has emerged as an important tool in the diagnosis of neurosarcoidosis and MRI is the preferred imaging technique with high sensitivity but low specificity.
- To describe a patient that highlights the diagnostic challenges encountered with diagnosis of neurosarcoidosis

History of Present Illness

- Patient J.G. is a 53-year-old otherwise healthy man who presented with a 7-year history of slowly progressive distal greater than proximal leg weakness, initially affecting the left leg, and more recently the right. He also reports diffuse left leg numbness, urinary urgency and constipation. He endorses night sweats and a 30 pound weight loss in recent months. He denies neurologic symptoms other than those noted above.

PMH & PSH & Medications

- BPH, herniated disc (L4-5)
- Colonoscopy
- Meds: Naproxen PRN

Social and Family History

- SH: Drinks 2-3 beers daily. Prior smoker. Smokes marijuana occasionally. Lives with mother.
- FH: Mother has rheumatoid arthritis and father died of metastatic colon cancer
- ROS: numbness in feet and left buttock, urinary urgency and occasional difficulty voiding, constipation. Denies visual changes, new rashes, upper extremity sensory changes or weakness.

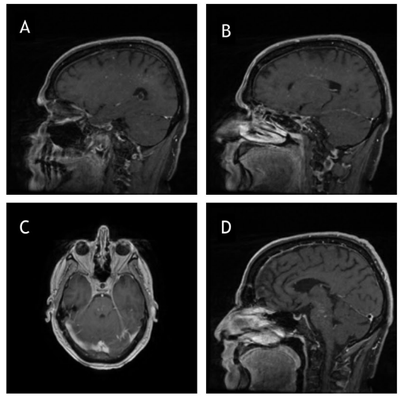

Figure 1: MRI brain
(A) T2 hyperintensity of multiple punctate foci of enhancement involving cerebral white matter
(B) T2 hyperintensity of linear foci of enhancement involving cerebral white matter
(C) T2 axial view shows punctate foci of enhancement involving pons
(D) T2 hyperintensity of multiple punctate foci of enhancement involving pons.

Results

Neurologic Exam (notable):

-Bilateral distal>proximal leg weakness, leg spasticity, 3+ patellar reflexes with absent Achilles reflexes, reduced vibratory sense of 5 seconds at bilateral great toes and mild cognitive impairment (Montreal Cognitive Assessment score 25/30).

Labs

CSF: 22 nucleated cells/mm^3 (lymphocytic predominance), elevated protein of 291 mg/dL, and normal glucose.

CSF angiotension-converting enzyme (ACE): 4.4 U/L.

- Negative CSF testing included cytology, oligoclonal bands, AQP-4 IgG and fungal cultures.
- Negative AQP-4 IgG, HIV, RPR, anti-double-stranded DNA, anti-SSB/SSA, and HTLV 1/2.

Imaging:

- Chest CT: scattered sub-centimeter mediastinal lymph nodes and pulmonary nodules.
- MRI brain: extensive small T2 hyperintensities in the bilateral cerebral white matter, basal ganglia and pons, including multiple areas of linear and punctate enhancement.
- MRI lumbar spine: heterogeneously enhancing T2 intramedullary hyperintensity spanning T10 through the conus medullaris.
- A gallium scan showed abnormal increased uptake in bilateral hilar lymph nodes and left cerebellopontine region in a pattern

Discussion

Sarcoidosis is a chronic, idiopathic, multi-systemic granulomatous disorder which can present in a variety of ways often mimicking other disorders[1,2]. Although the lymphatic and pulmonary systems are most commonly affected, neurological involvement is seen in 5-13% of cases, either in isolation or along with other systemic features[1]. Neurosarcoidosis is a heterogeneous disorder with variable clinical manifestations affecting both the central and peripheral nervous system[2]. The most common presentations include cranial neuropathy, basal meningitis, hypothalamic-pituitary dysfunction, encephalopathy and other symptoms related to intraparenchymal brain manifestations[3]. Spinal cord and peripheral nerve involvement are seen in 15% and 40% of cases respectively[2].

The most widely used guideline for diagnosis is the modified Zajicek's criteria which takes into account clinical, pathological and other paraclinical evidence[3]. Although tissues diagnosis is ideal, often times, neurological tissue is inaccessible. Other tools which can help to support the diagnosis include neuroimaging, CSF analysis, chest imaging to look for hilar adenopathy, serum and CSF ACE, FDG-PET (fluorodeoxyglucose positron emission tomography) or gallium scan to look for systemic areas of high metabolic activity[4].

Neuroimaging has emerged as an important tool in the diagnosis of neurosarcoidosis and MRI is the preferred imaging technique with high sensitivity but low specificity4. Neurosarcoidosis has variable MRI presentations as shown in the table below. Our patient presented with punctate and linear MRI enhancement in the cerebral hemispheres and brainstem (Figure 1). This feature has been reported in neurosarcoidosis and occurs due to certain unique pathological characteristics as described below.

In contrast to other disorders like multiple sclerosis, MRI enhancement in neurosarcodosis tends to be in a linear, punctate and/or patchy fashion along Virchow-Robin spaces[1]. Virchow-Robin spaces are CSF filled perivascular channels existing between the vascular adventitia and pia-glia membrane. These spaces communicate with cervical lymphatics and may represent the interface between the immune system and the brain[3,5]. Virchow-Robin spaces have been proposed as a possible path for the spread of neurosarcoidosis in the central nervous system (CNS)[5]. Lymphocytes and non-caseating granulomas are typically seen in the adventitia of medium and small sized arteries and veins right within these anatomical spaces[5]. This perivascular inflammatory activity along the outer layer of cerebral vessels gives rise to the punctate and linear enhancement pattern often seen in MRI imaging.

Table 1:
MRI Brain Findings in Neurosarcoidosis

Locations	Findings

Leptomeninges/pachymeninges	• *Thickening*
	• *Enhancement*
	  • *Smooth or nodular*
	  • *Diffuse or focal*
	  • *Basal meningeal involvement common*

Parenchyma	• *T2 hyperintensities*
	  • *Solitary or multifocal*
	• *Enhancement*
	  • *Punctate or linear pattern common*
	  • *Duration-months to years*

Cranial Nerves	• *Thickening or enhancement* • *Cranial nerve II commonly affected*
Pituitary/hypothalamus	• *Thickening or enhancement*
Ventricles	• *Hydrocephalus* • *Communicating or non-communicating*

Conclusion

The case described shows the diagnostic challenges that can be encountered in the diagnosis of neurosarcoidosis. Abnormal neuro-imaging, elevated CSF/serum ACE levels and evidence of increase metabolic activity on gallium scan or FDG-PET are all supportive for a diagnosis of neurosarcoidosis in the absence of tissue biopsy. Punctate and linear enhancement on neuro-MRI is a feature of neurosarcoidosis due to its unique CNS pathophysiology. Occurrence of this feature in the right clinical setting should raise the suspicion for neurosarcoidosis and prompt appropriate workup.

References

1. Lacomis D. Neurosarcoidosis. Current Neuropharmacology, 2011, 9, 429-436
2. Tana C, Wegener S, Borys E et al. Challenges in diagnosis and treatment of neurosarcoidosis. Annals of Medicine. Vol. 47, No. 7, 576-591
3. Tavee JO, Stern BJ. Neurosarcoidosis. Clin Chest Med 36 (2015) 643–656
4. MacLean HJ, Abdoli M. Neurosarcoidosis as an MS Mimic: The trials and tribulations of making a diagnosis. Multiple SclerosisandRelatedDisorders4(2015)414–429
5. Mirfakraee M, Crofford MJ, Guinto FC et al. Virchow-Robin Space: A path of spread of neurosarcodosis. Radiology 1986; 158:715-720