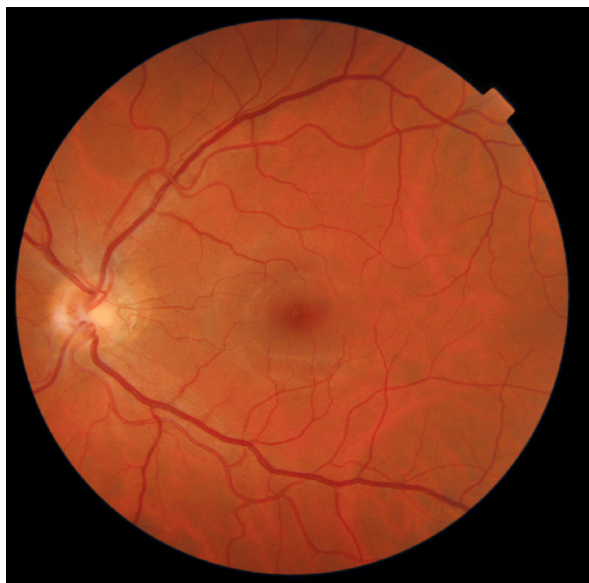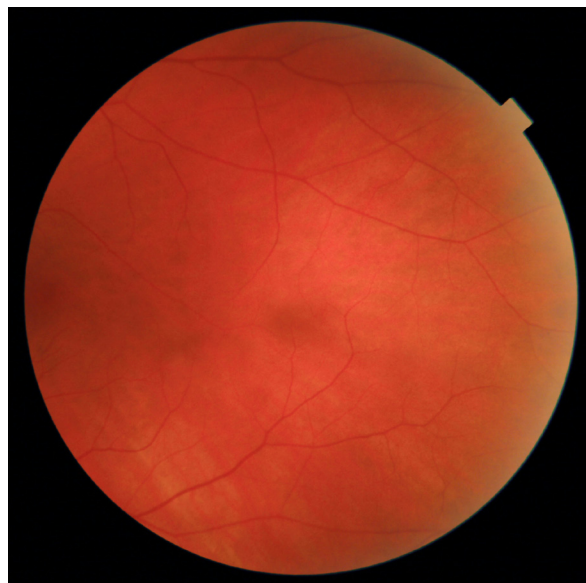


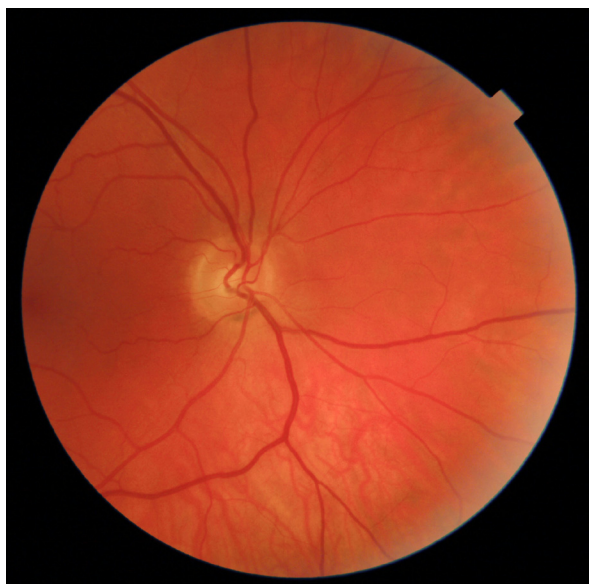Good Images; What your images should look like



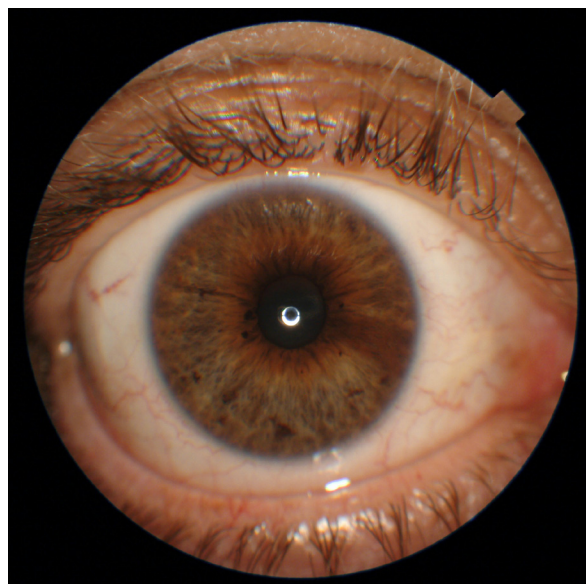Macula Centered



Temporal to Macula



Optic Disc Centered



External