

THE ROLE OF OCT IN DIAGNOSING OCULAR TUMORS

Prithvi Mruthyunjaya, MD, MHS

Associate Professor of Ophthalmology and Radiation Oncology

Director, Ocular Oncology Service

Director, Vitreoretinal Surgery Fellowship



Stanford

OPHTHALMOLOGY

BYERS EYE INSTITUTE

DISCLOSURES

Consultant:

- Alcon
- Arix Biosciences
- Aura Biosciences
- Castle Biosciences

Patent provisional

- PCT Application Serial No. US2021/015830

Funding:




National Eye Institute
(P30-026877)

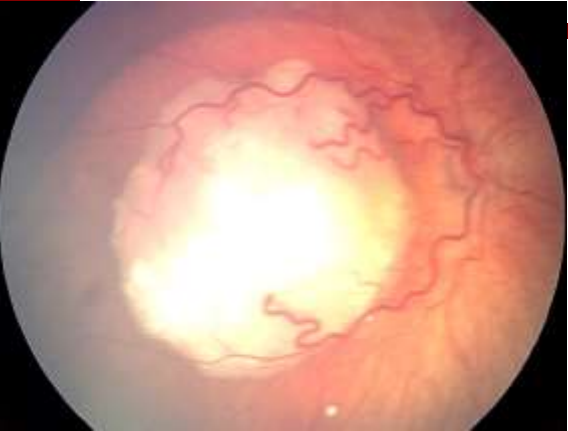

Research to
Prevent Blindness

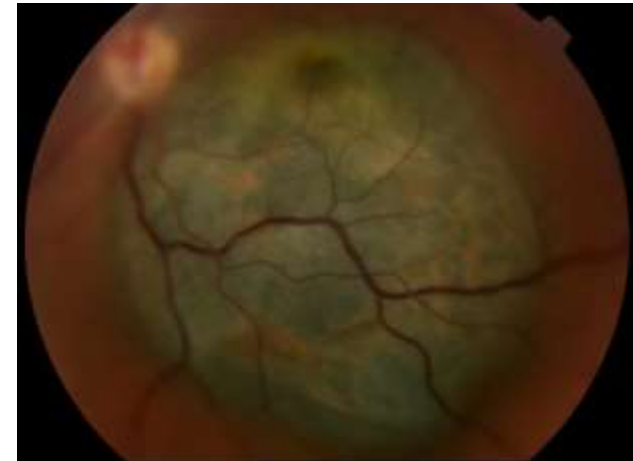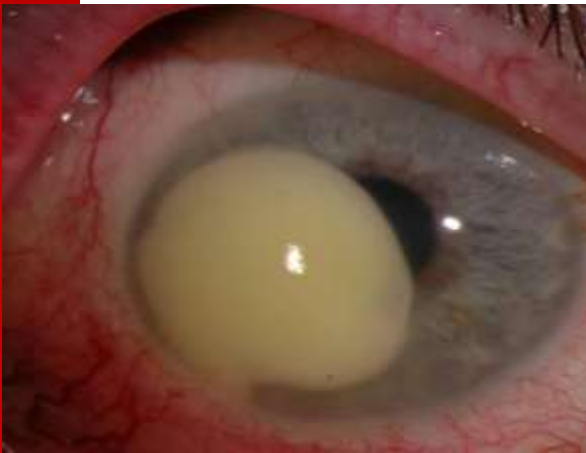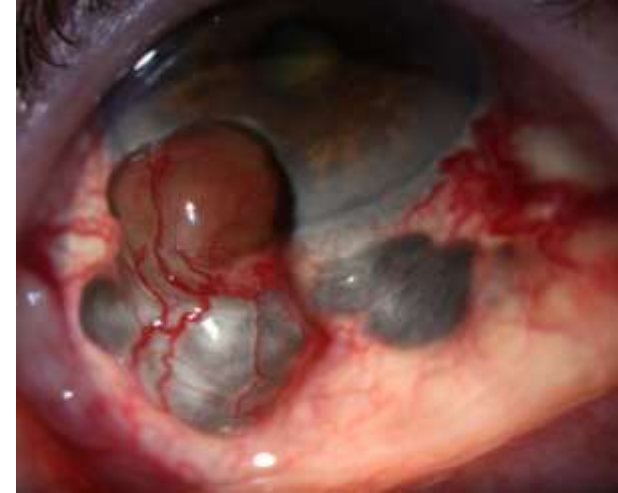- The Cancer League
- Retina Research Foundation/
The Macula Society



I AM AN OCULAR ONCOLOGIST @ STANFORD




- Comprehensive care of
 - cancerous,
 - pre-cancerous and
 - simulating conditions in and around the eye
- Impact of treatments of systemic cancers on the eye
- Spans all specialties in Ophthalmology



THE ROLE OF OCT IN DIAGNOSING OCULAR TUMORS

- How do we diagnose ocular tumors
- OCT in ocular oncology
 - How, what, and why?
- Anterior segment tumors
- Posterior segment tumors
- Novel frontiers



ACCURATE DIAGNOSIS IMPACTS


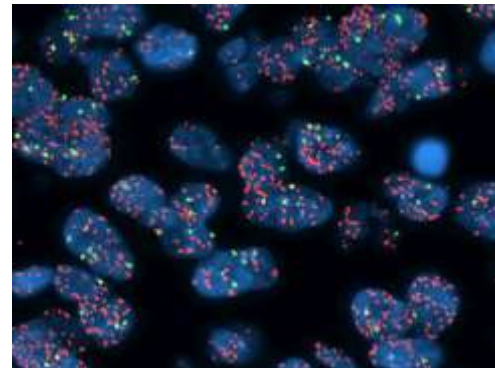
Patient counseling/
decision making

Observe ↔ Treat

Choice of primary/adjuvant therapy
Tumor specific therapies

Plaque
Chemo ↔ Resect
Enucleate

Systemic prognosis
Future systemic screening
Clinical trial entry



MULTIMODAL IMAGING IN OCULAR ONCOLOGY

Photography

- lesion borders
- document

Ultrasound

- Thickness
- Internal reflectivity

Autofluorescence

- confirm lipofuscin
- RPE status

OCT

- thickness
- morphology
- Surface features

OCT Angiography

- radiation vascular changes
- flow in vascular tumors

Fluorescein Angiography

- vascular patterns
- response to therapy
- radiation complications



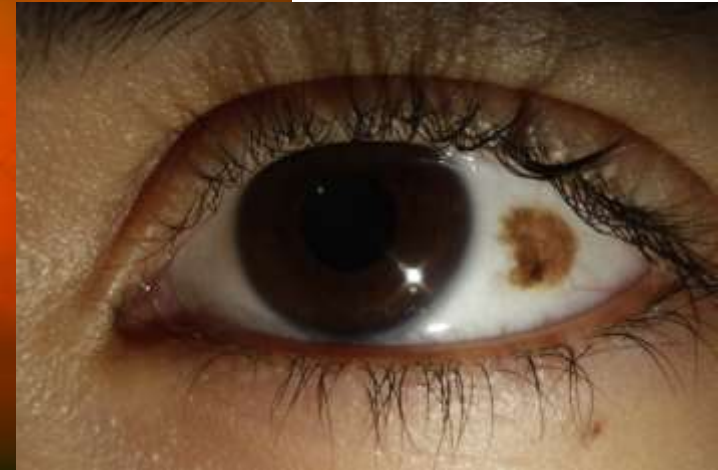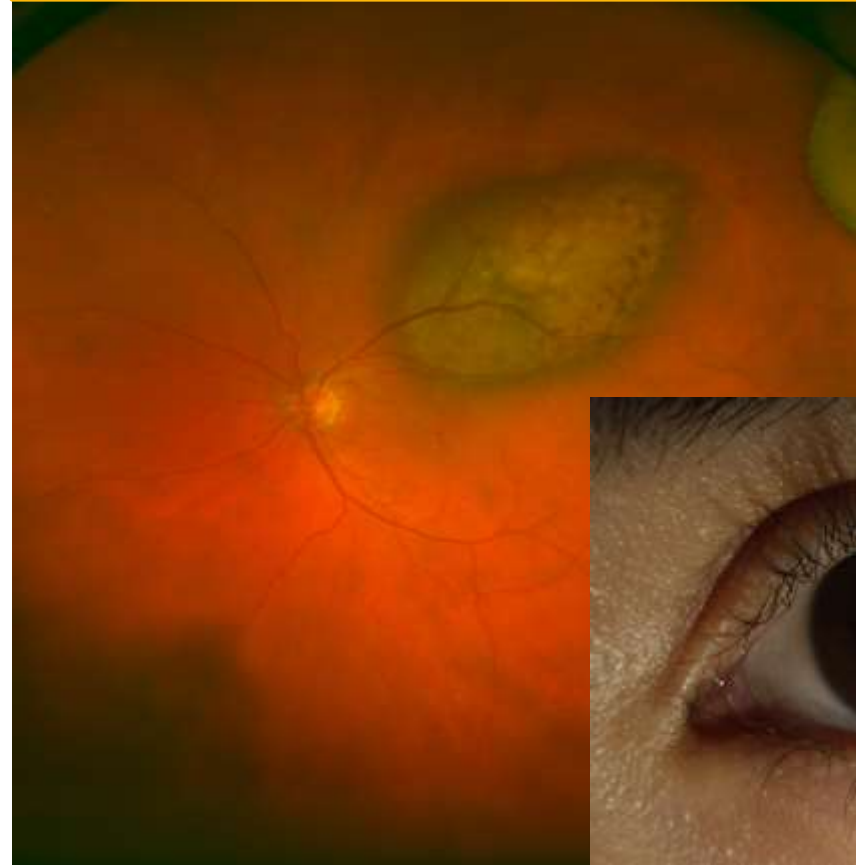MULTIMODAL IMAGING IN OCULAR ONCOLOGY

Photography

- lesion borders
- documentation

TIP:

Always try to take a picture

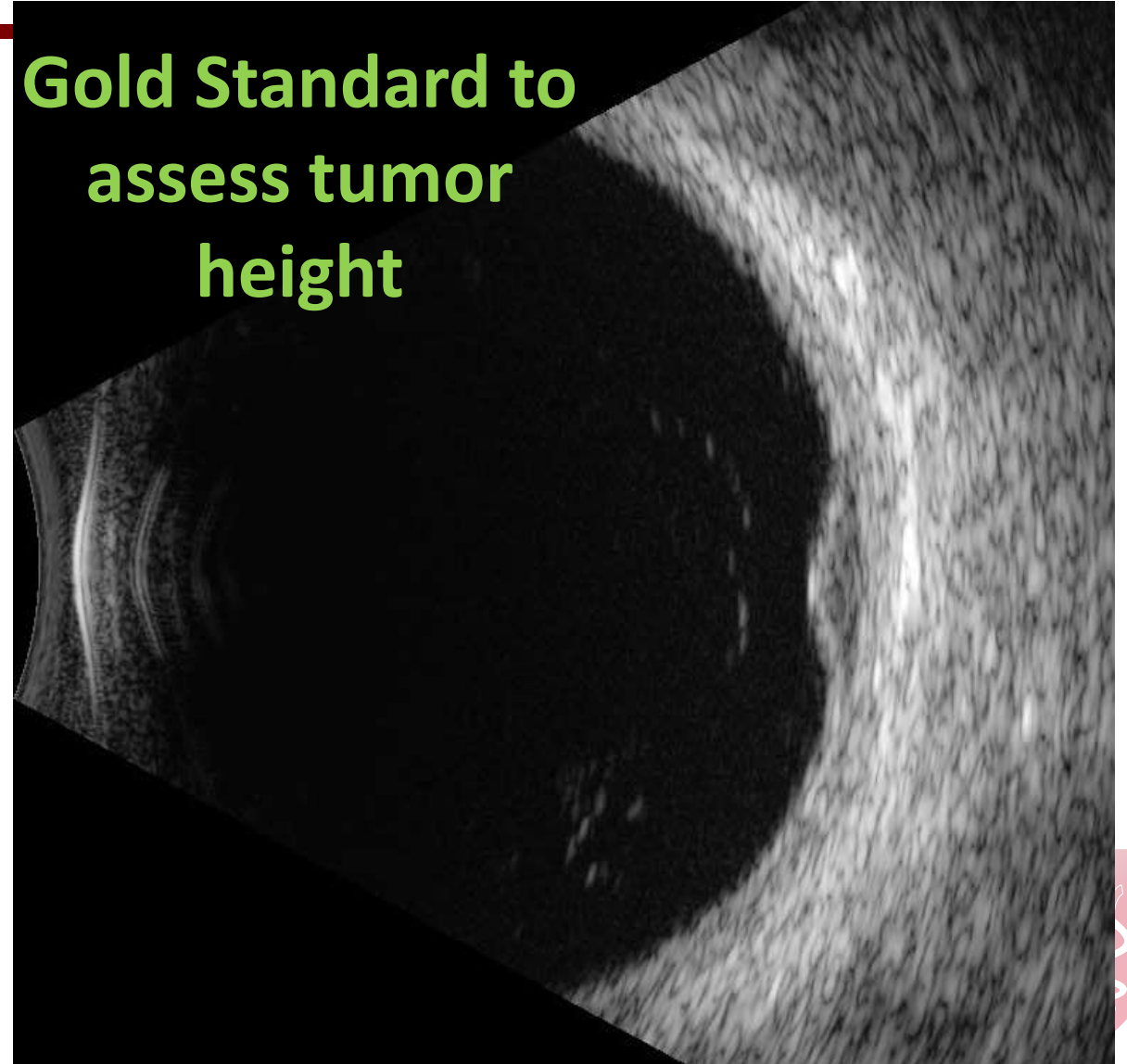


MULTIMODAL IMAGING IN OCULAR ONCOLOGY

Ultrasound

- Thickness
- Internal reflectivity

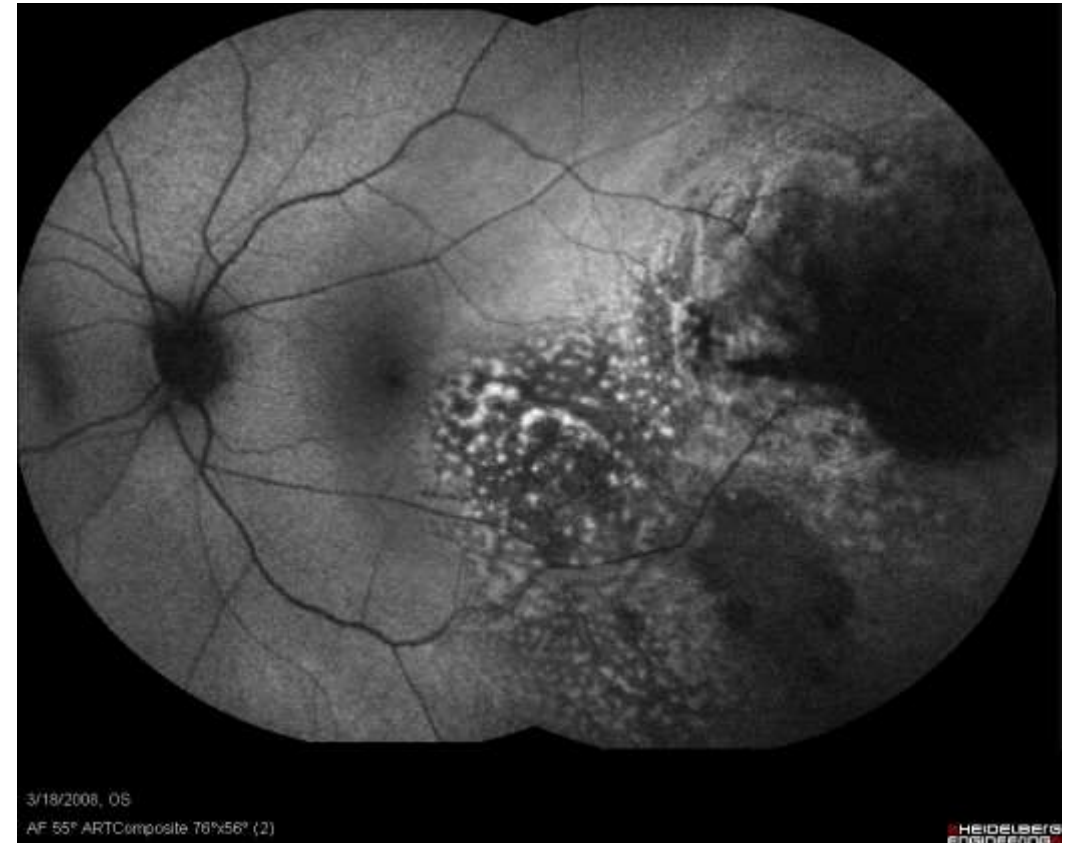
Gold Standard to
assess tumor
height



MULTIMODAL IMAGING IN OCULAR ONCOLOGY

Autofluorescence

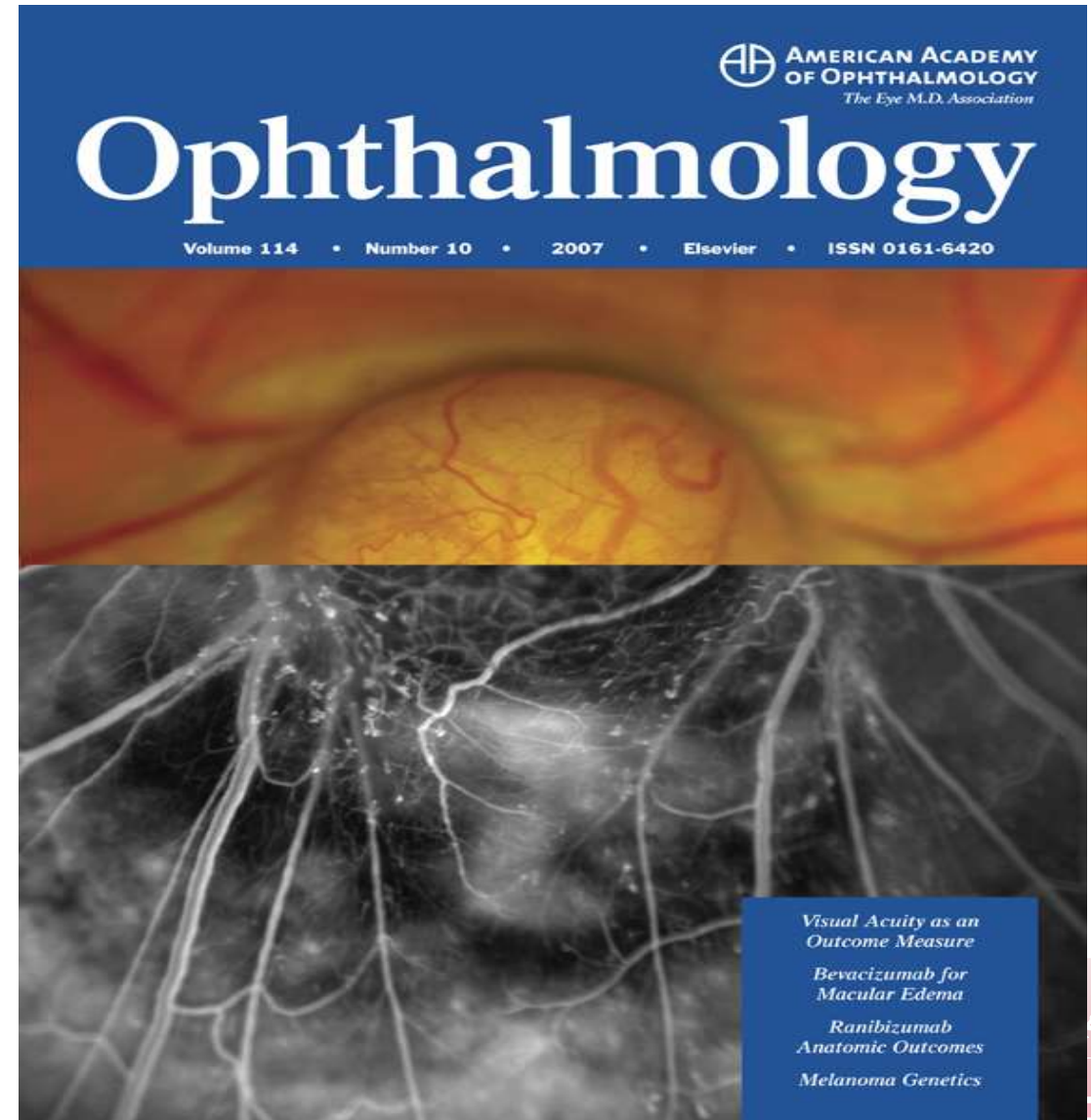- Confirm lipofuscin
- RPE status

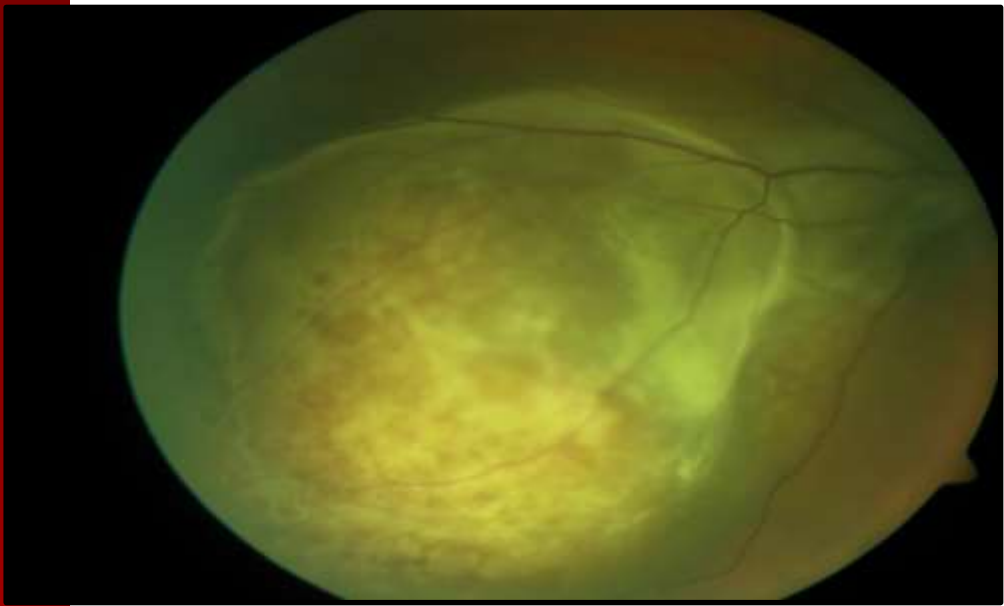


MULTIMODAL IMAGING IN OCULAR ONCOLOGY

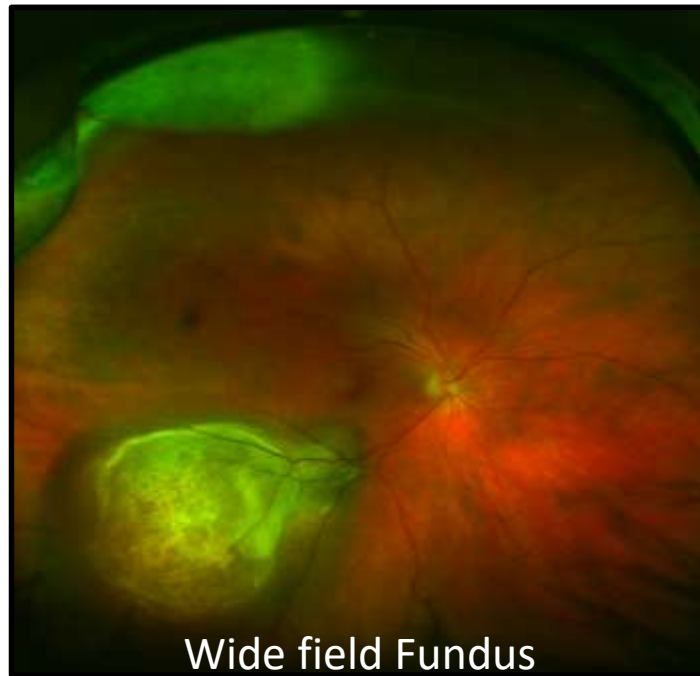Fluorescein Angiography

- vascular patterns
- response to therapy
- radiation complications

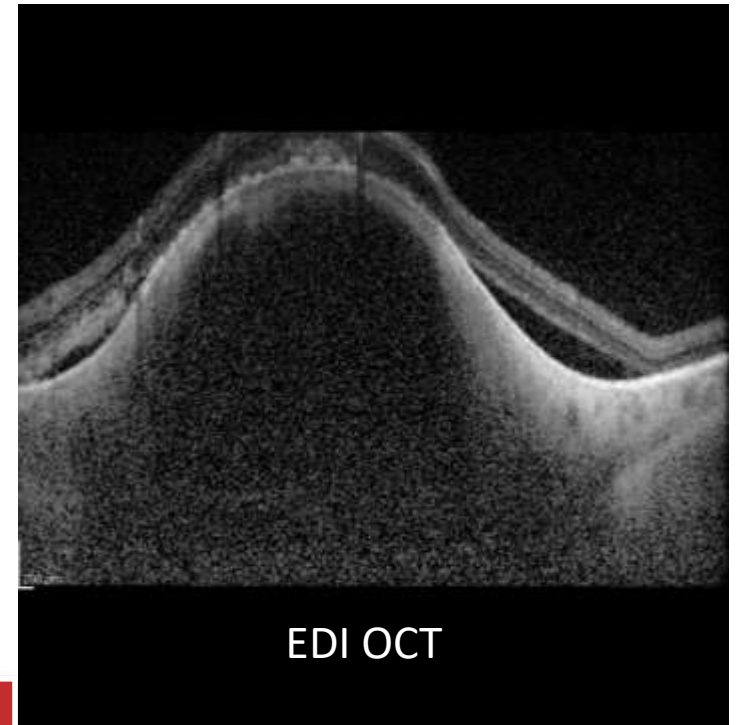




Standard Fundus

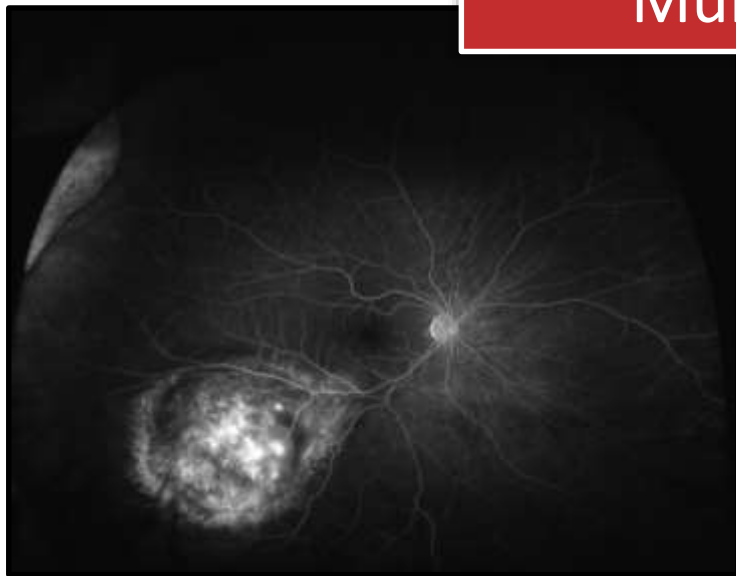


Wide field Fundus

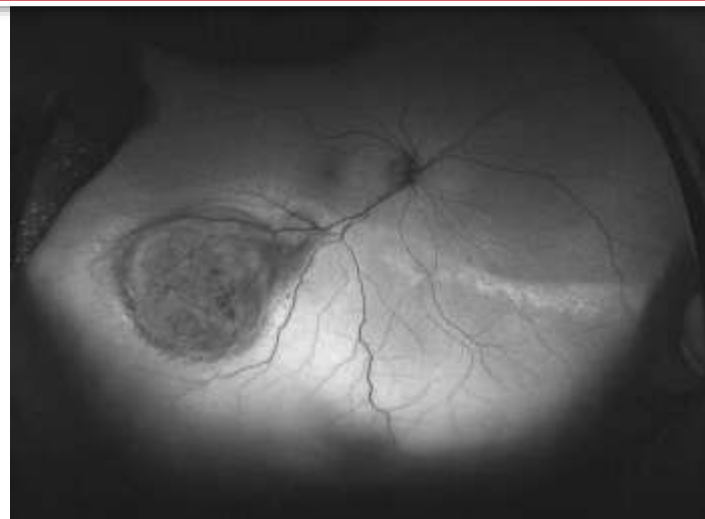


EDI OCT

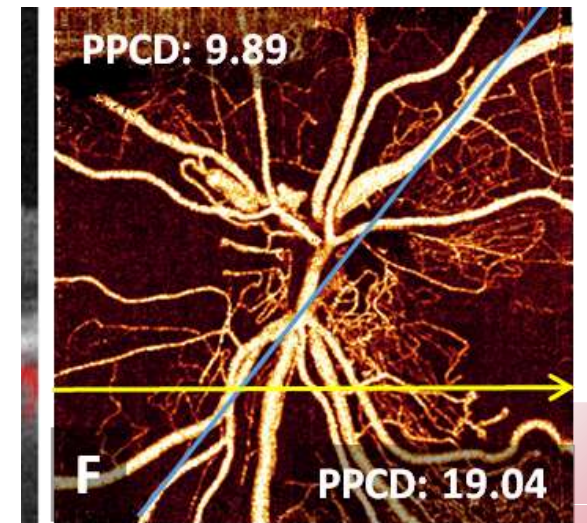
Multi-modal tumor imaging



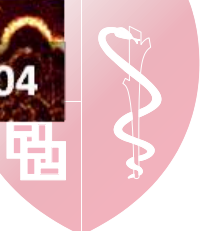Wide Field Angiography



Wide field Autofluorescence

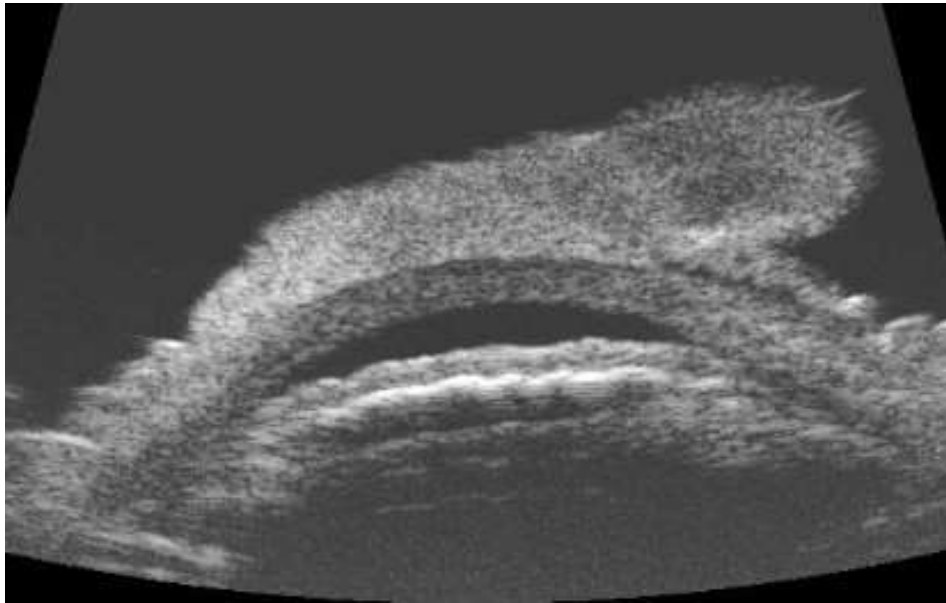


OCT-angiography


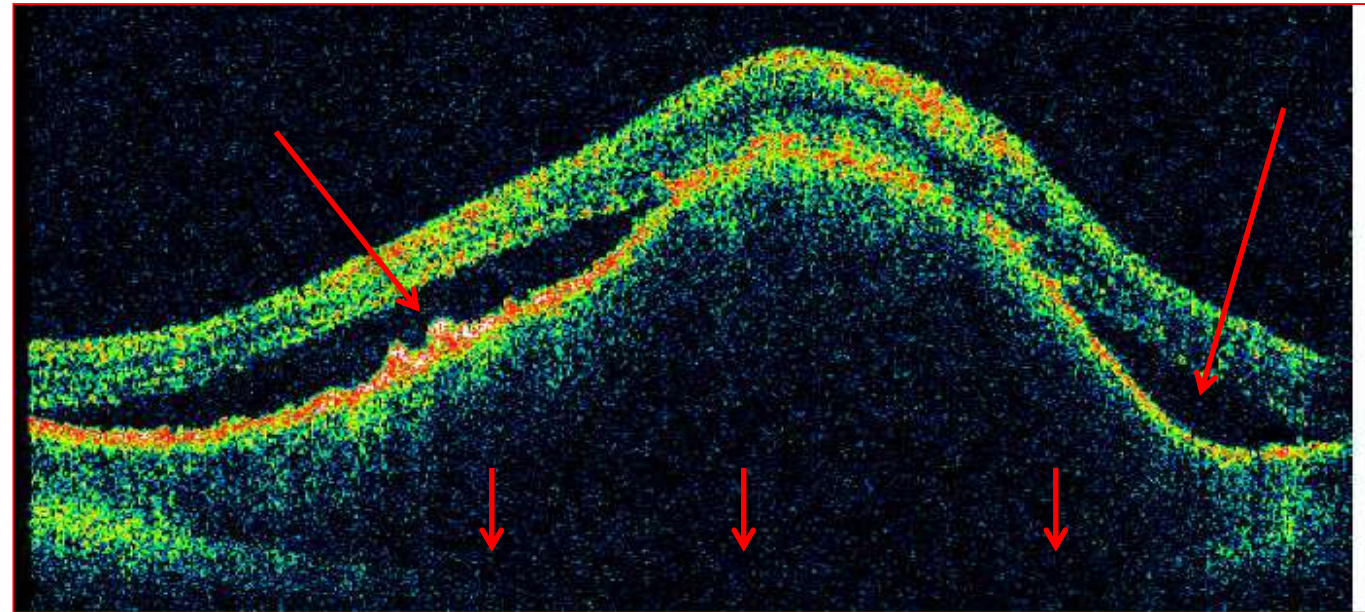



USE OF OCT IN OCULAR TUMORS

Anterior Segment




Posterior Segment

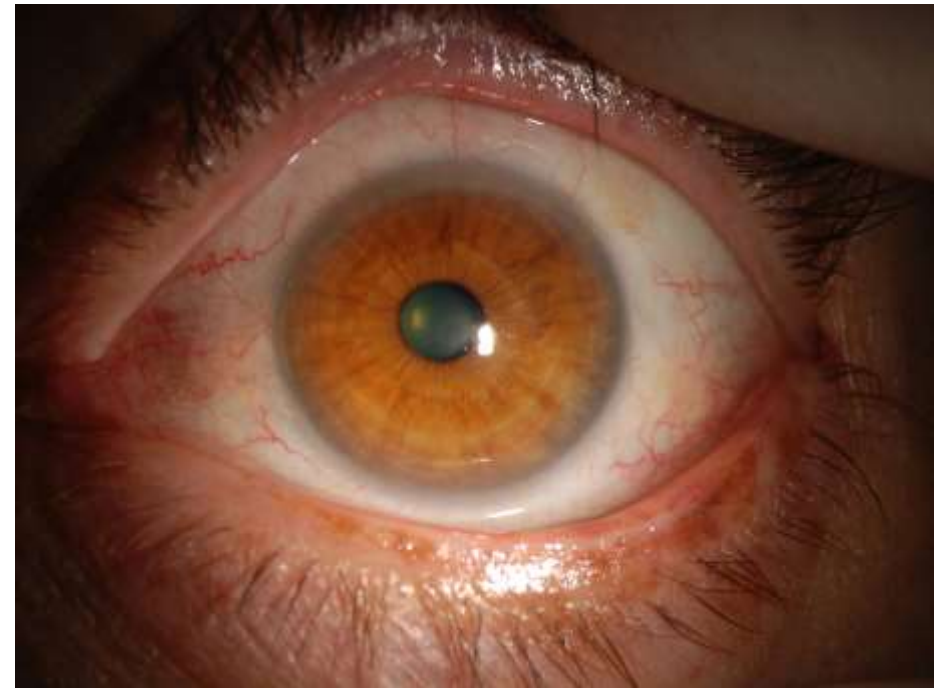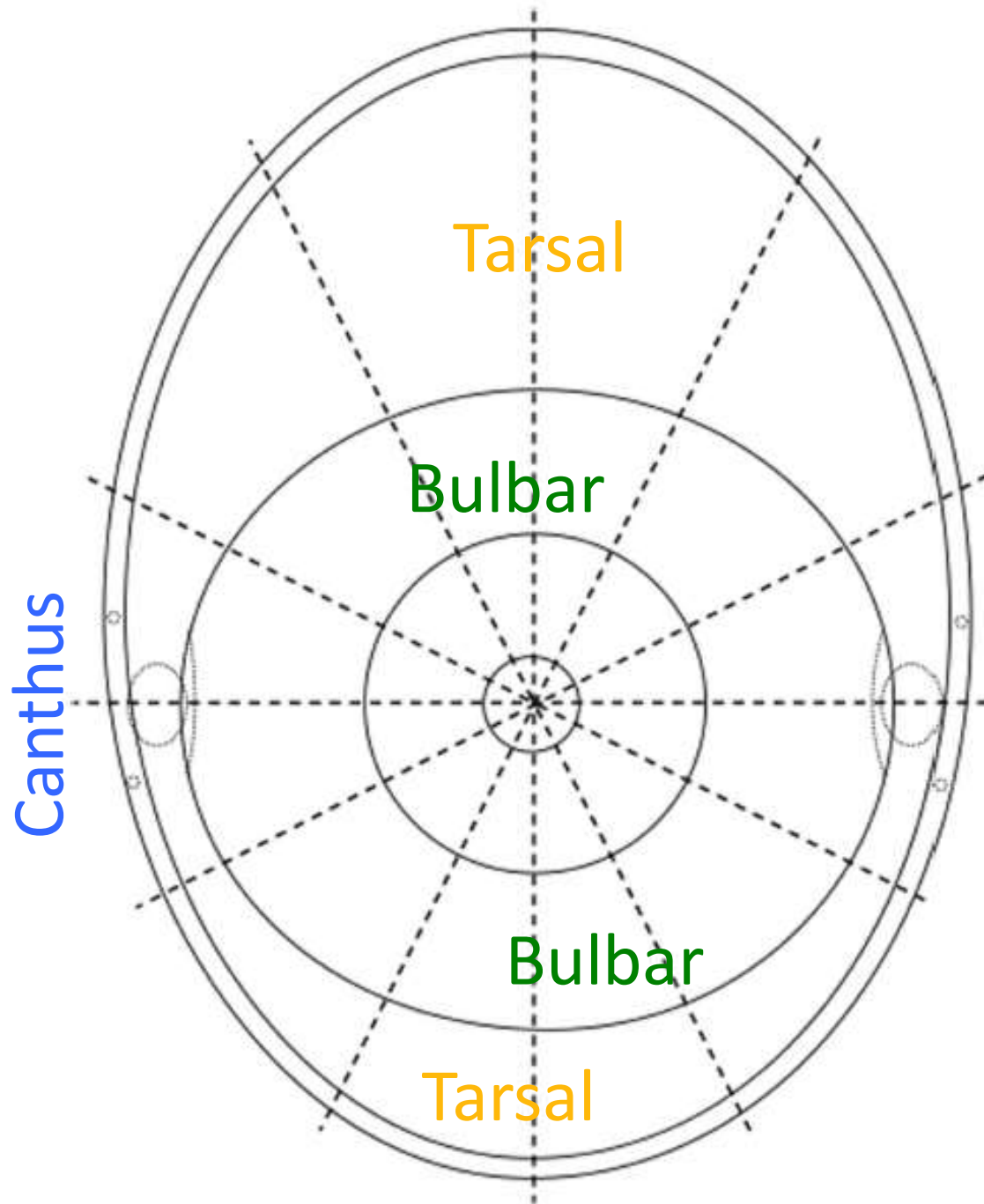





OCT AND ANTERIOR SEGMENT TUMORS

- **Determine level of involvement**
 - Epithelial disease (squamous neoplasia)
 - Sub epithelial disease (pingecula, nevus)
 - Iris disease
- Monitor treatment response


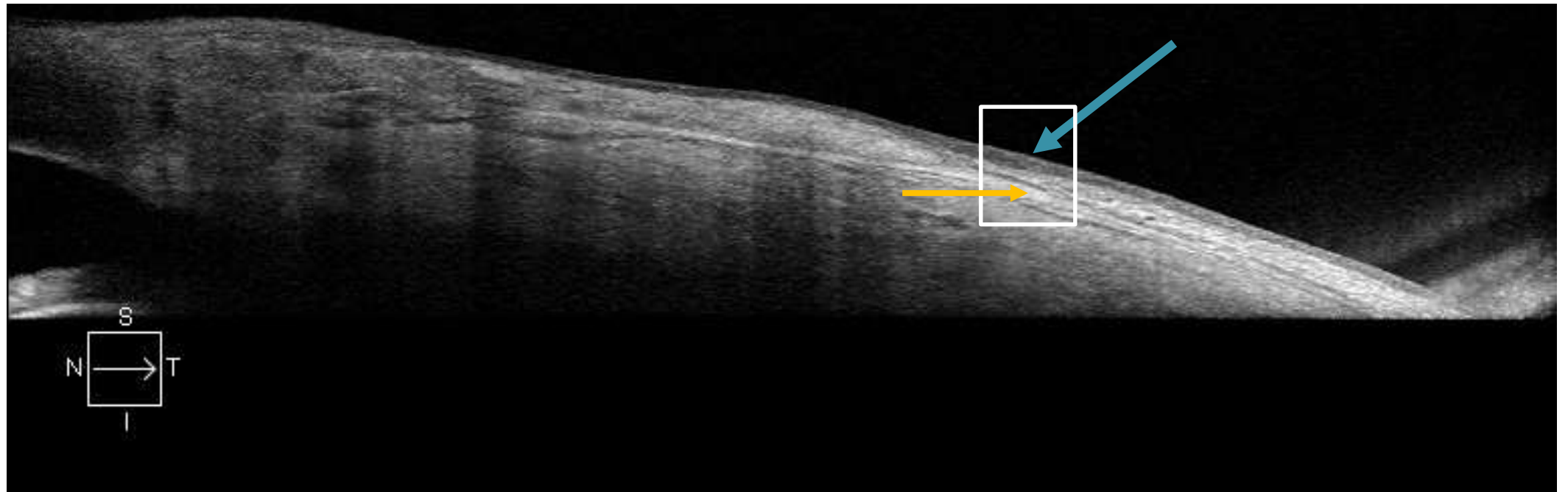




>50% of
conjunctival
surface is not
readily visible


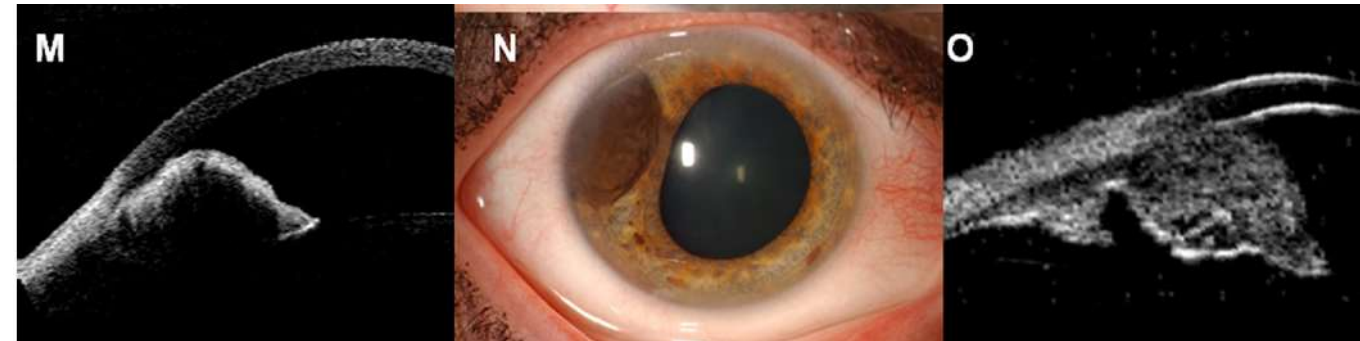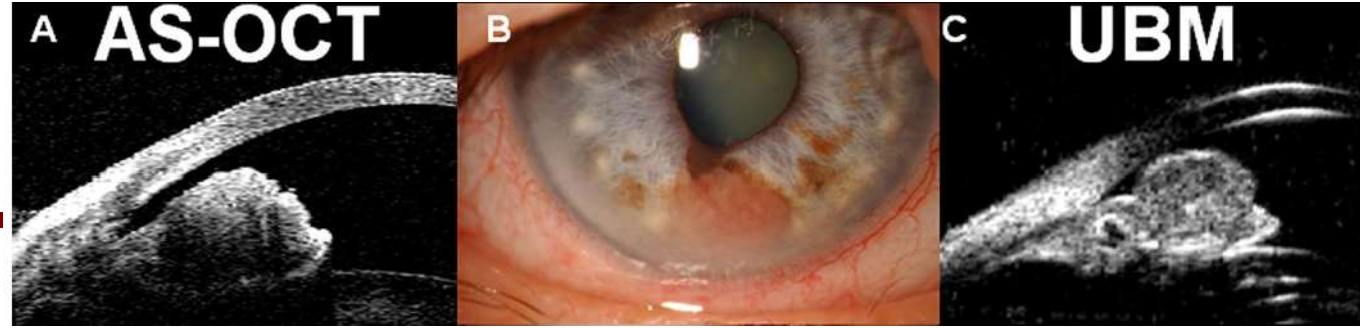


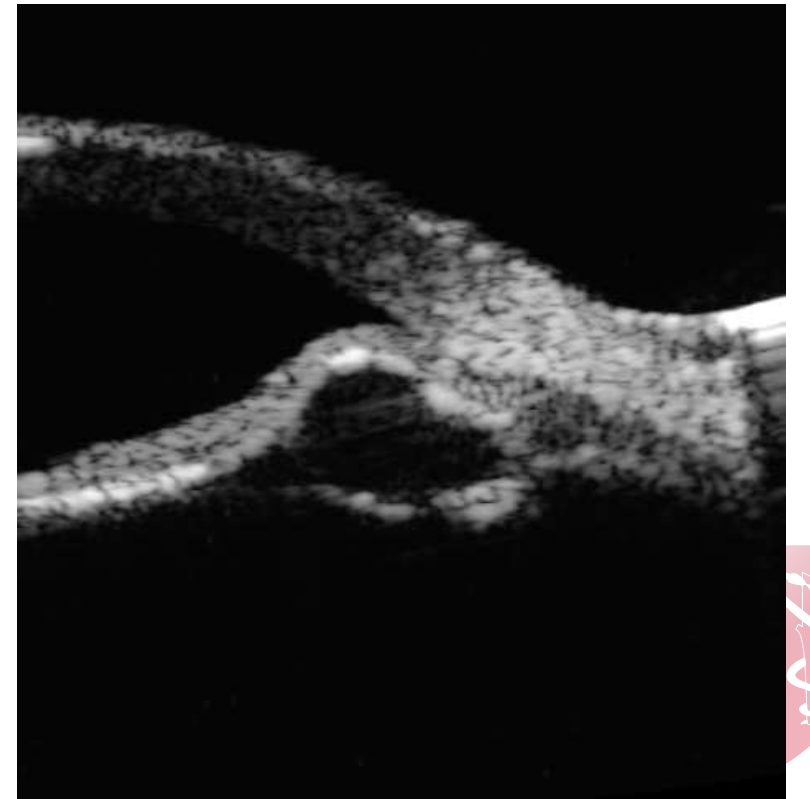
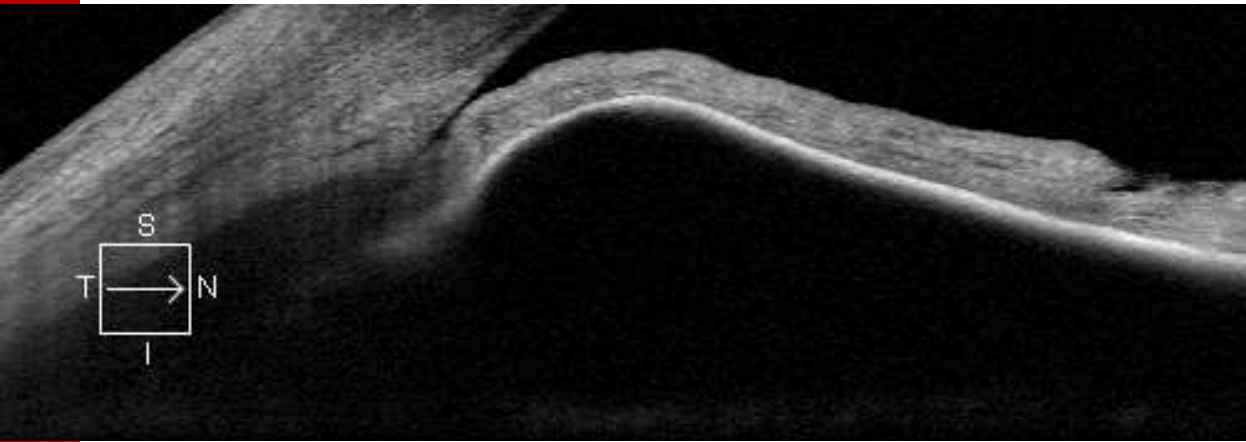
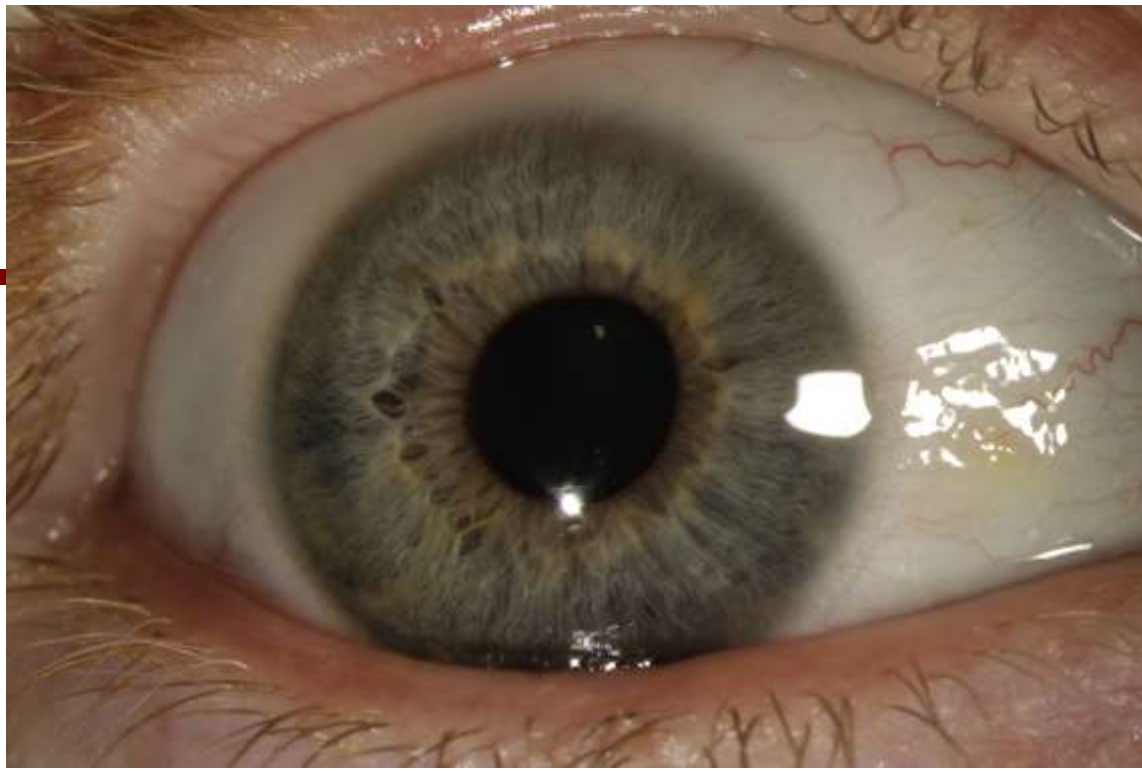
NORMAL CONJUNCTIVAL EPITHELIUM ON OCT



AS-OCT vs. UBM

- UBM demonstrates
 - Acoustic features,
 - Thickness and base
 - Configuration
- AS-OCT demonstrates
 - Posterior tumor shadowing





OCULAR SURFACE SQUAMOUS NEOPLASIA

MALIGNANT EYE TUMOR

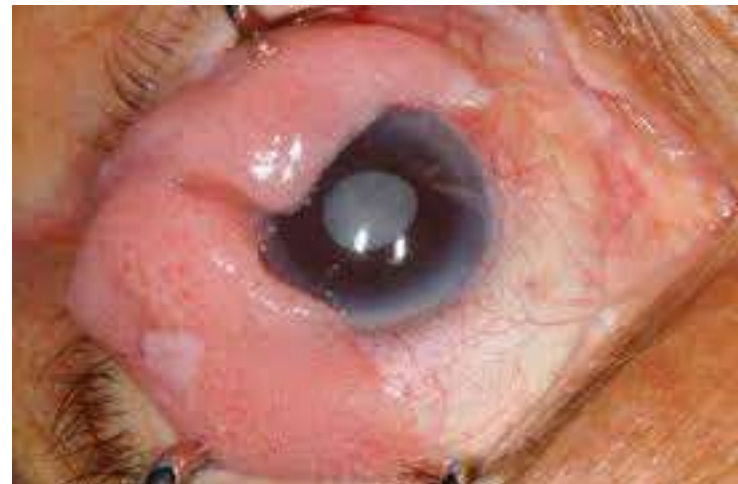OSSN

Conjunctival
Intraepithelial
Neoplasia

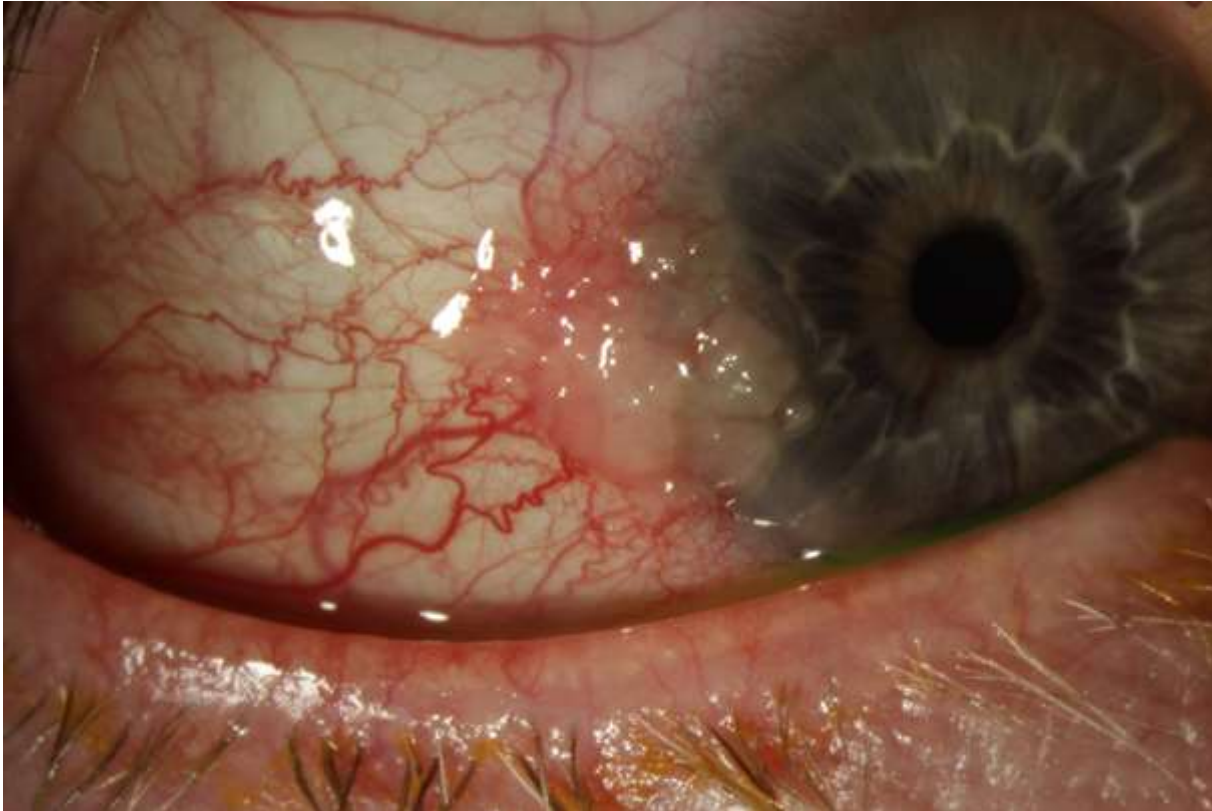


Squamous
Cell
carcinoma

- Young males, sun exposure
- Chance to treat at early stages



CLINICAL FINDINGS

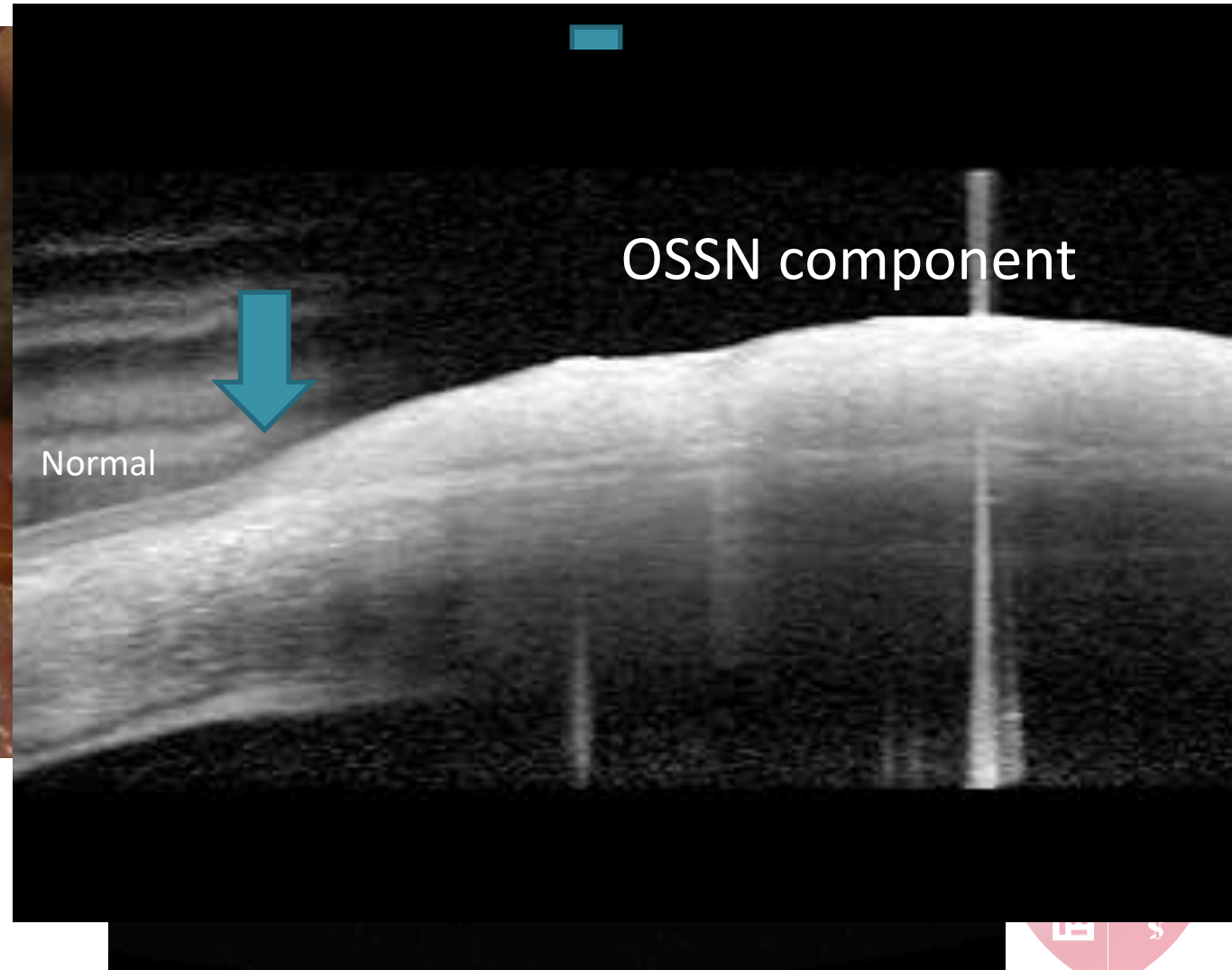
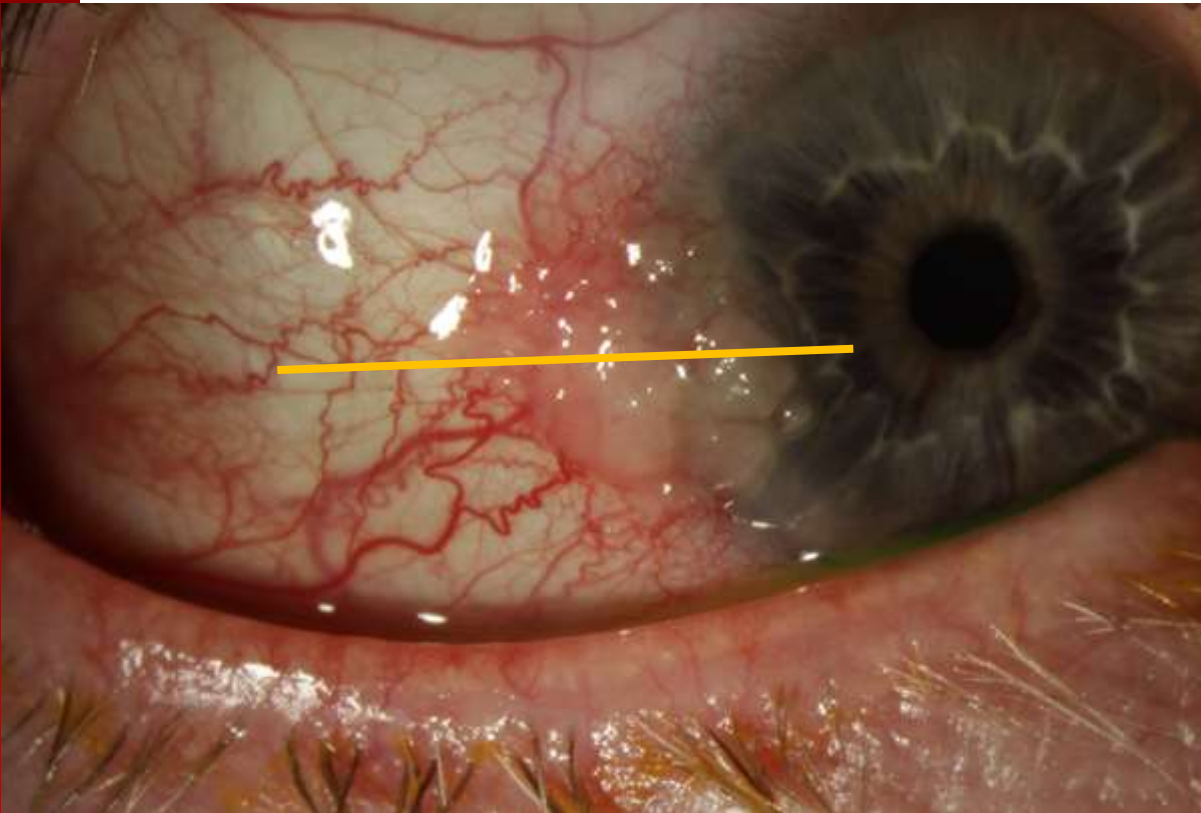


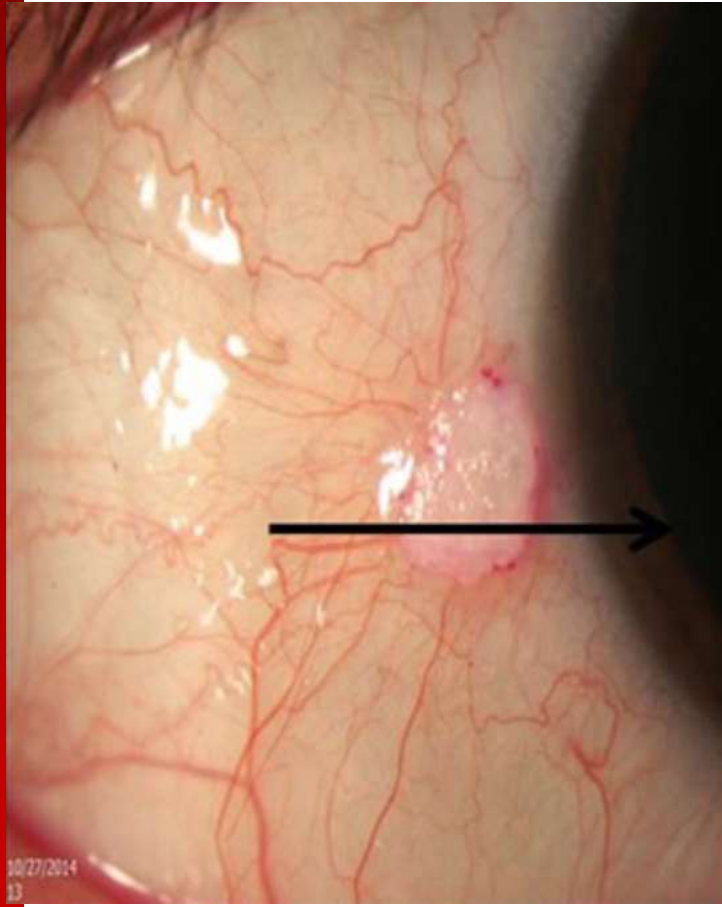
- Straddle nasal or temporal limbus in interpalpebral zone (>95%)
- Unilateral, elevated, variably shaped, feeder vessels, gray to red gray



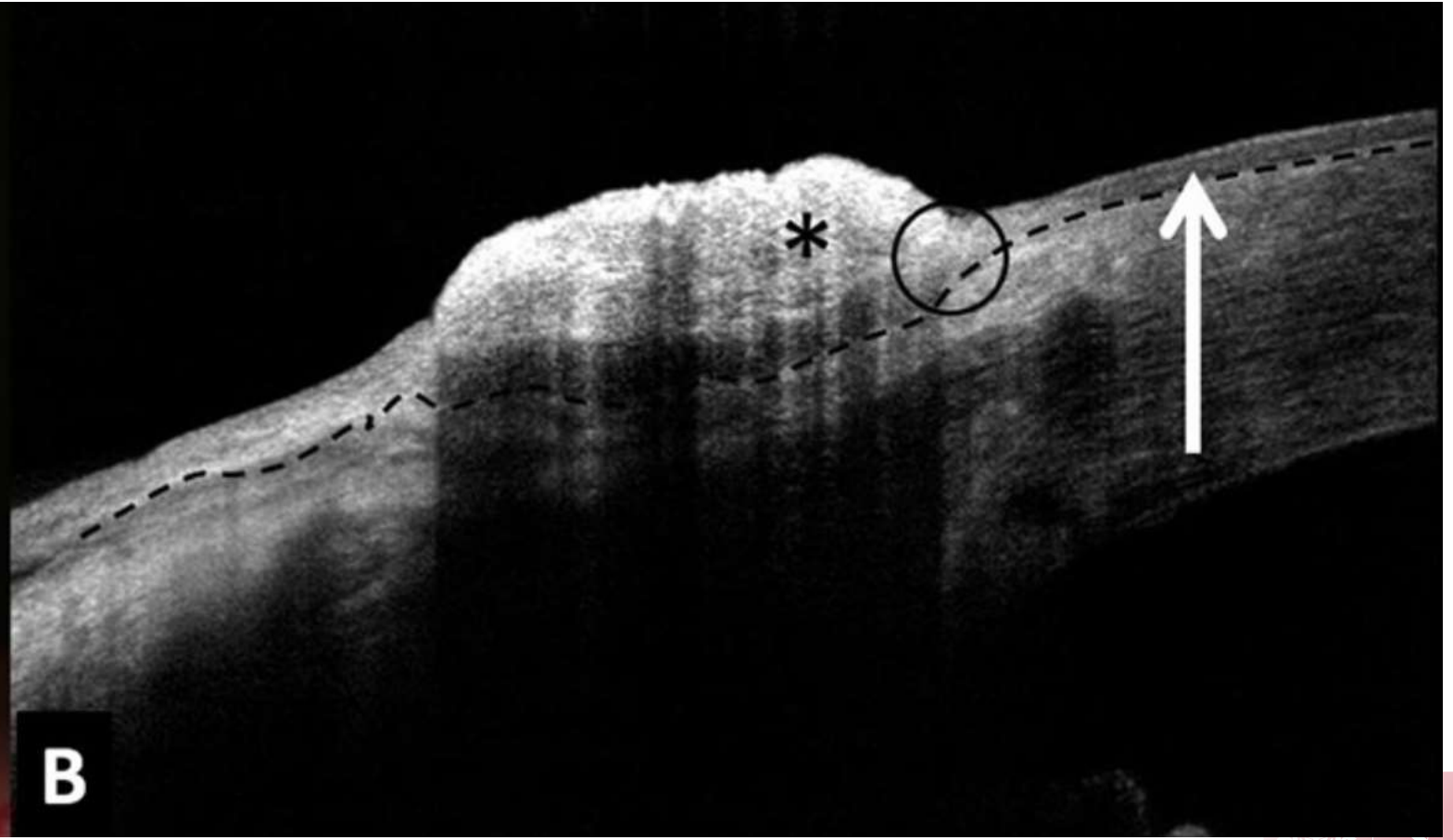
OSSN ON OCT :

FIND THE ABRUPT EPITHELIAL TRANSITION





A

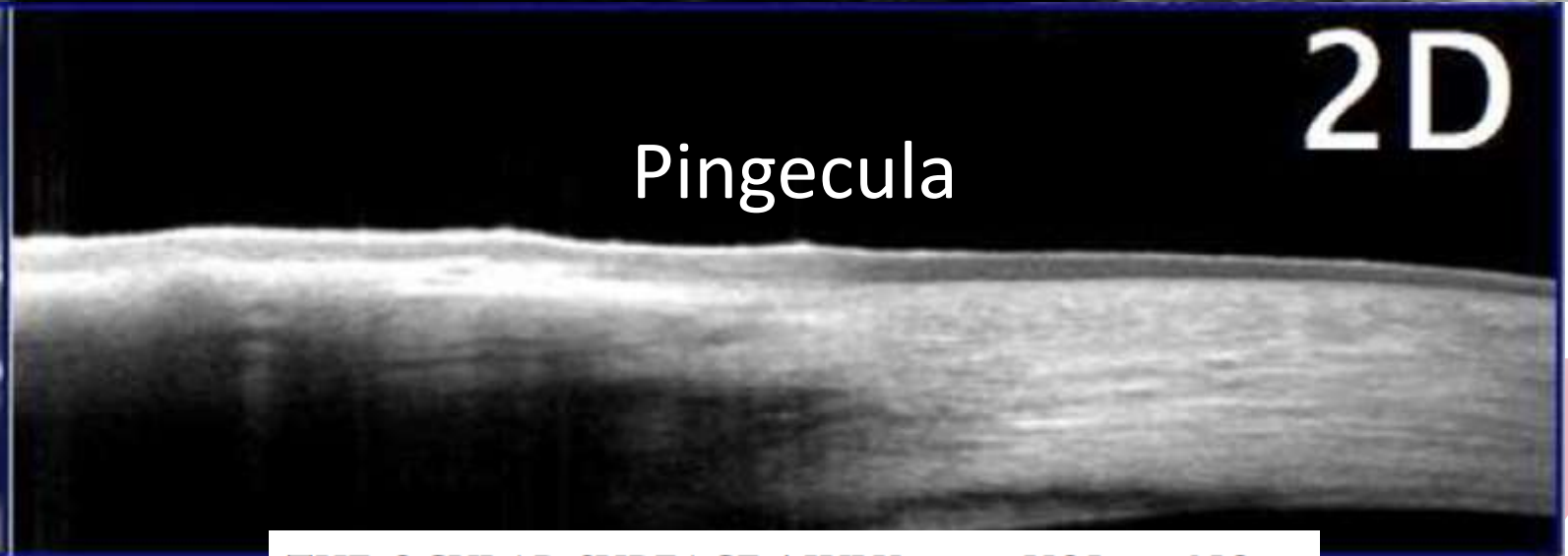
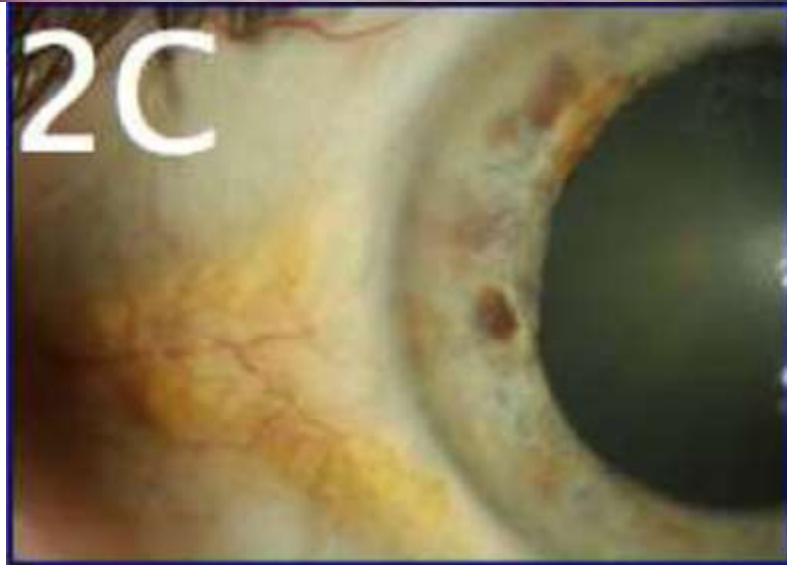
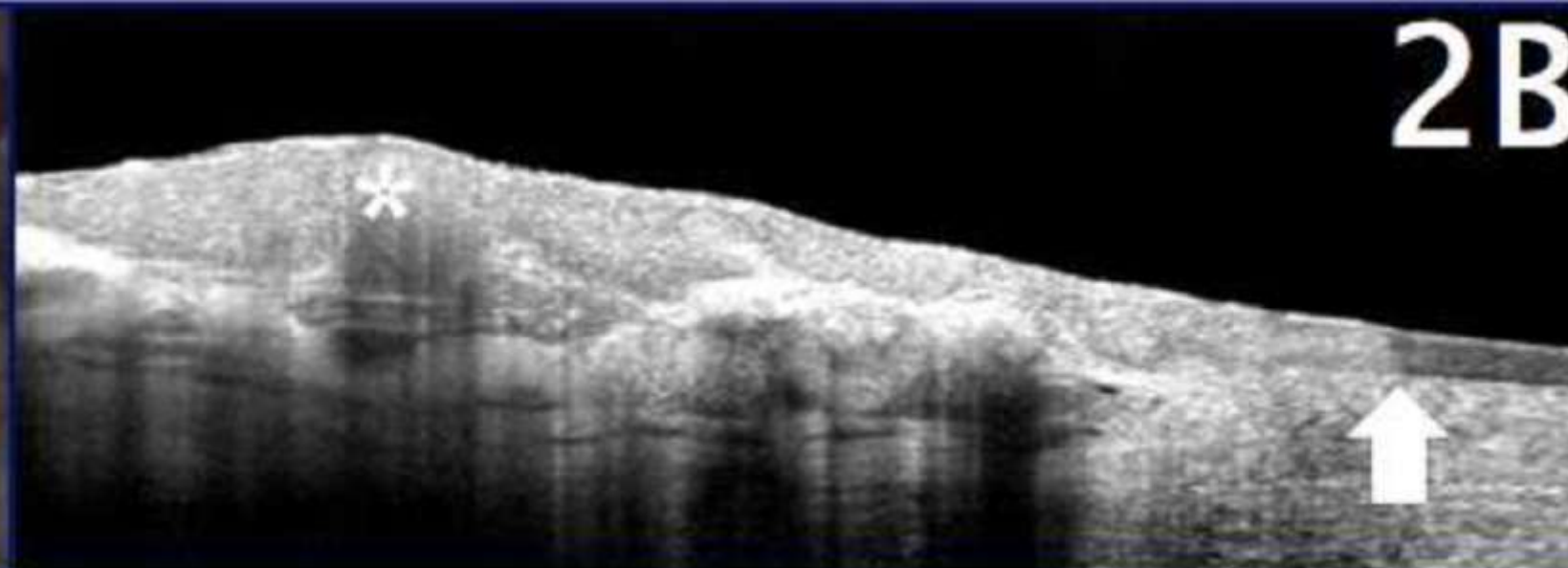
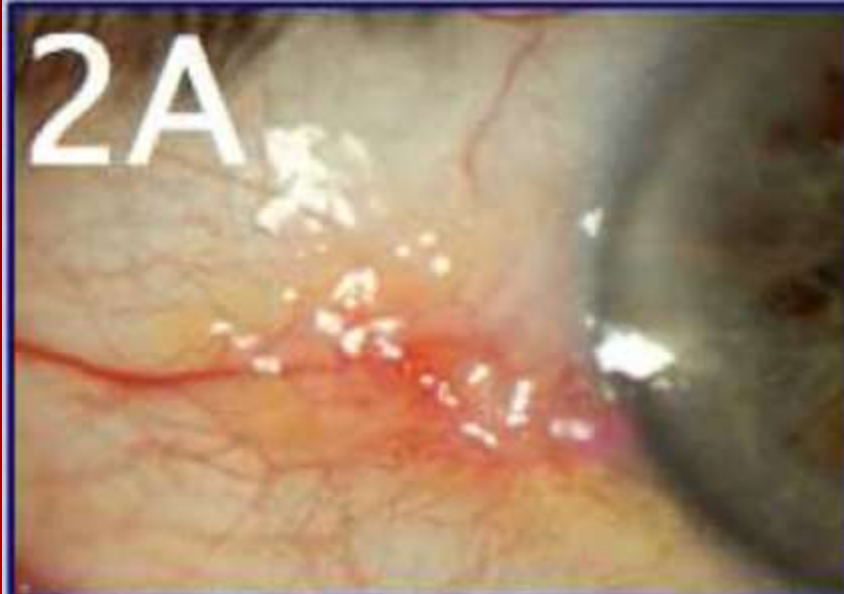

B

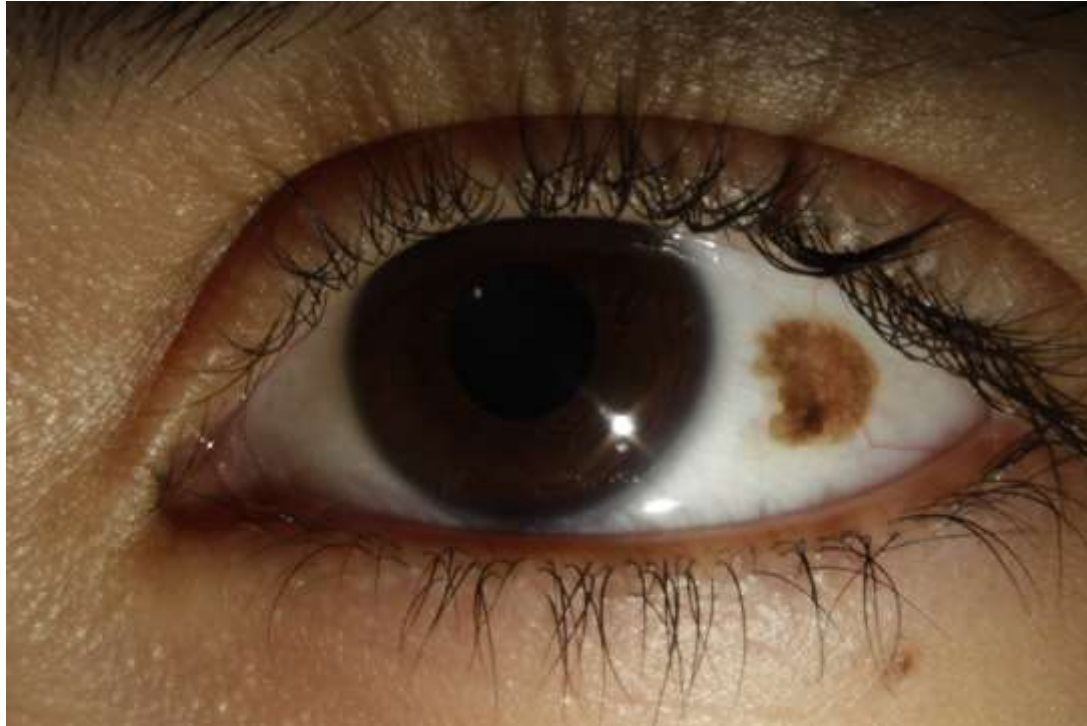10/27/2014
13




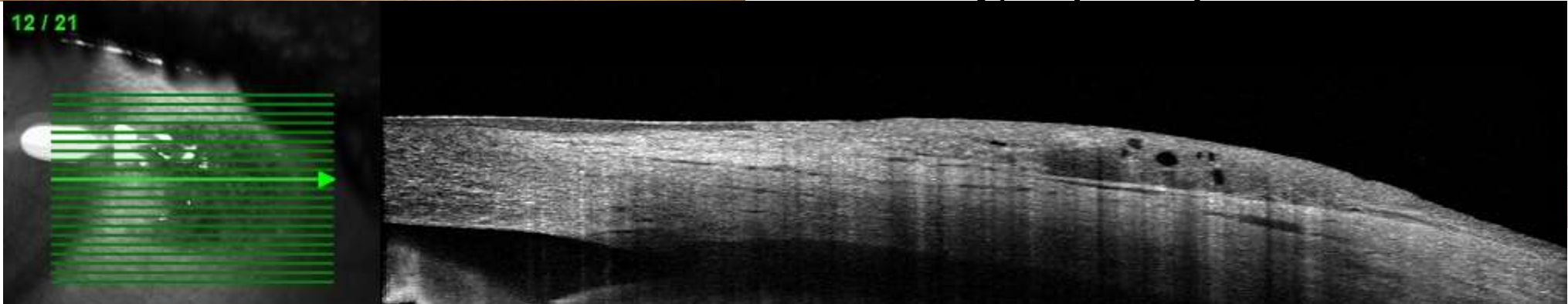
PINGECULAE HAVE NORMAL EPITHELIUM



CONJUNCTIVAL NEVUS

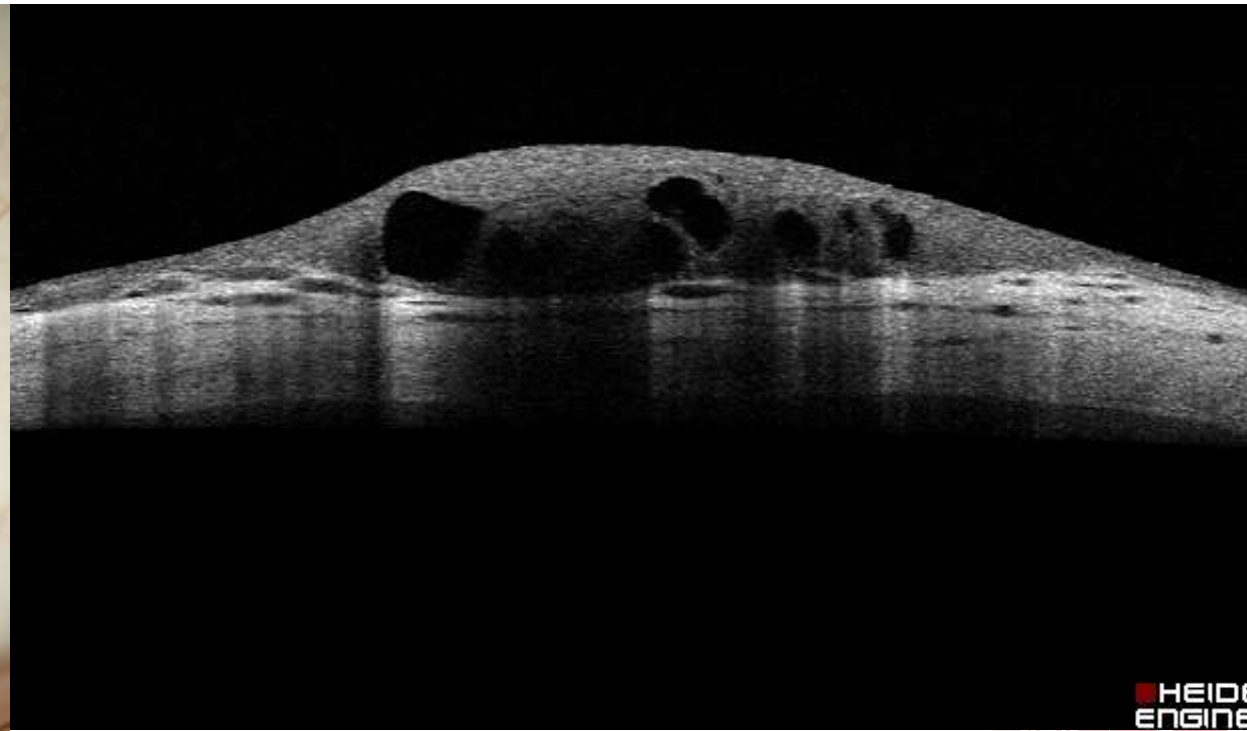
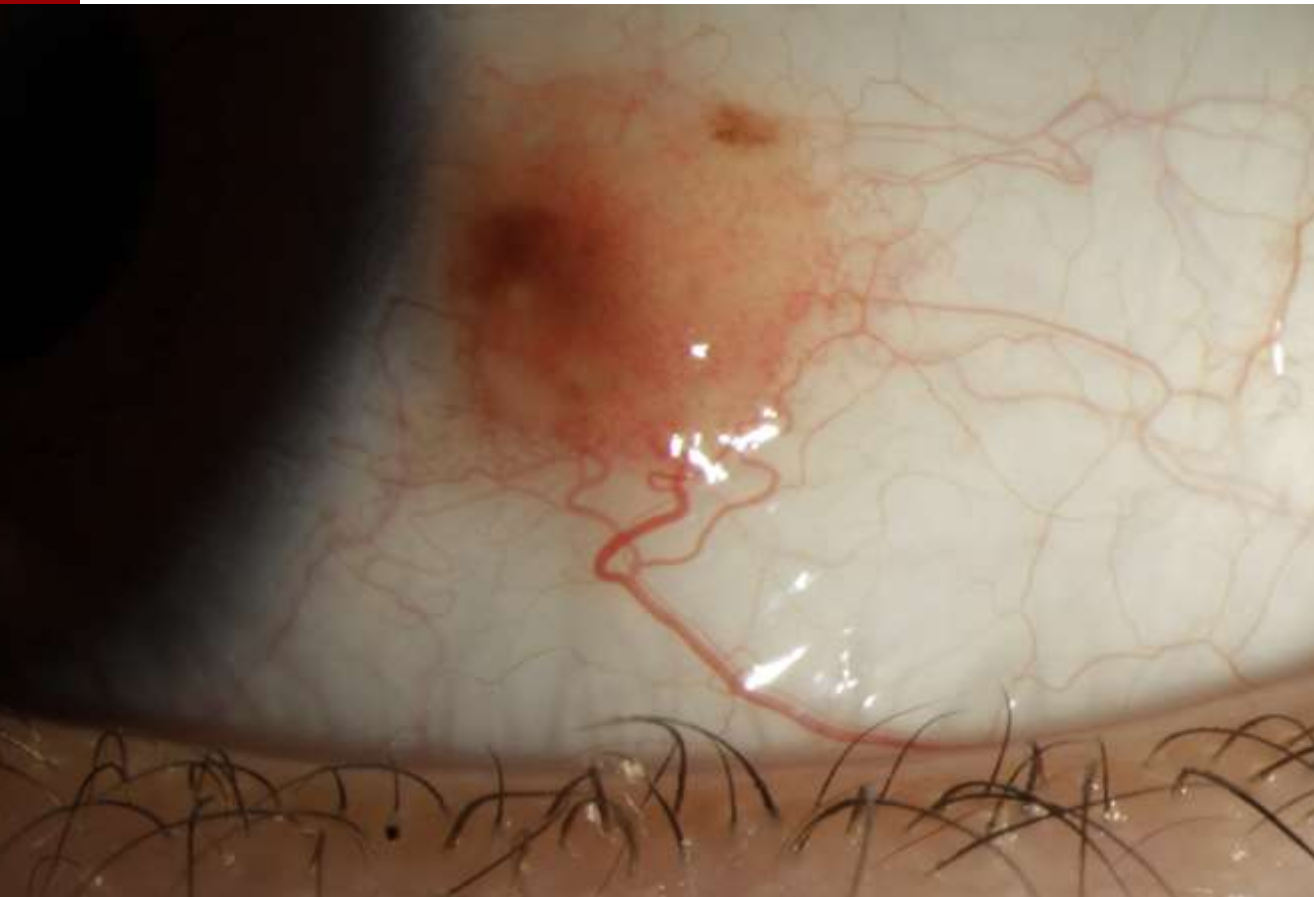

- Benign circumscribed lesion
- Hormonal influence
- Minimal thickening

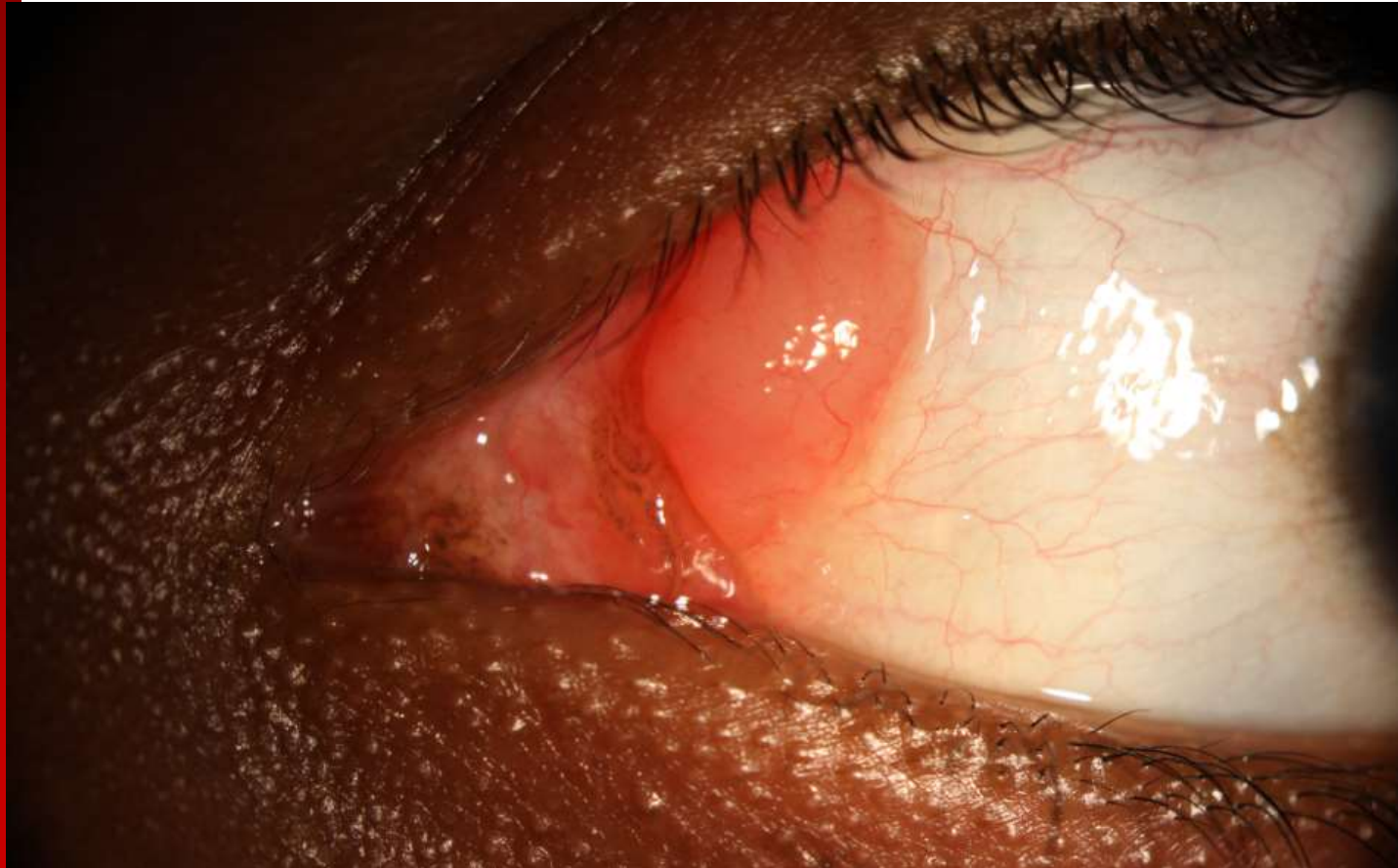


CONJUNCTIVAL NEVUS ON OCT


Full thickness involvement and CYSTS



CONJUNCTIVAL LYMPHOMA

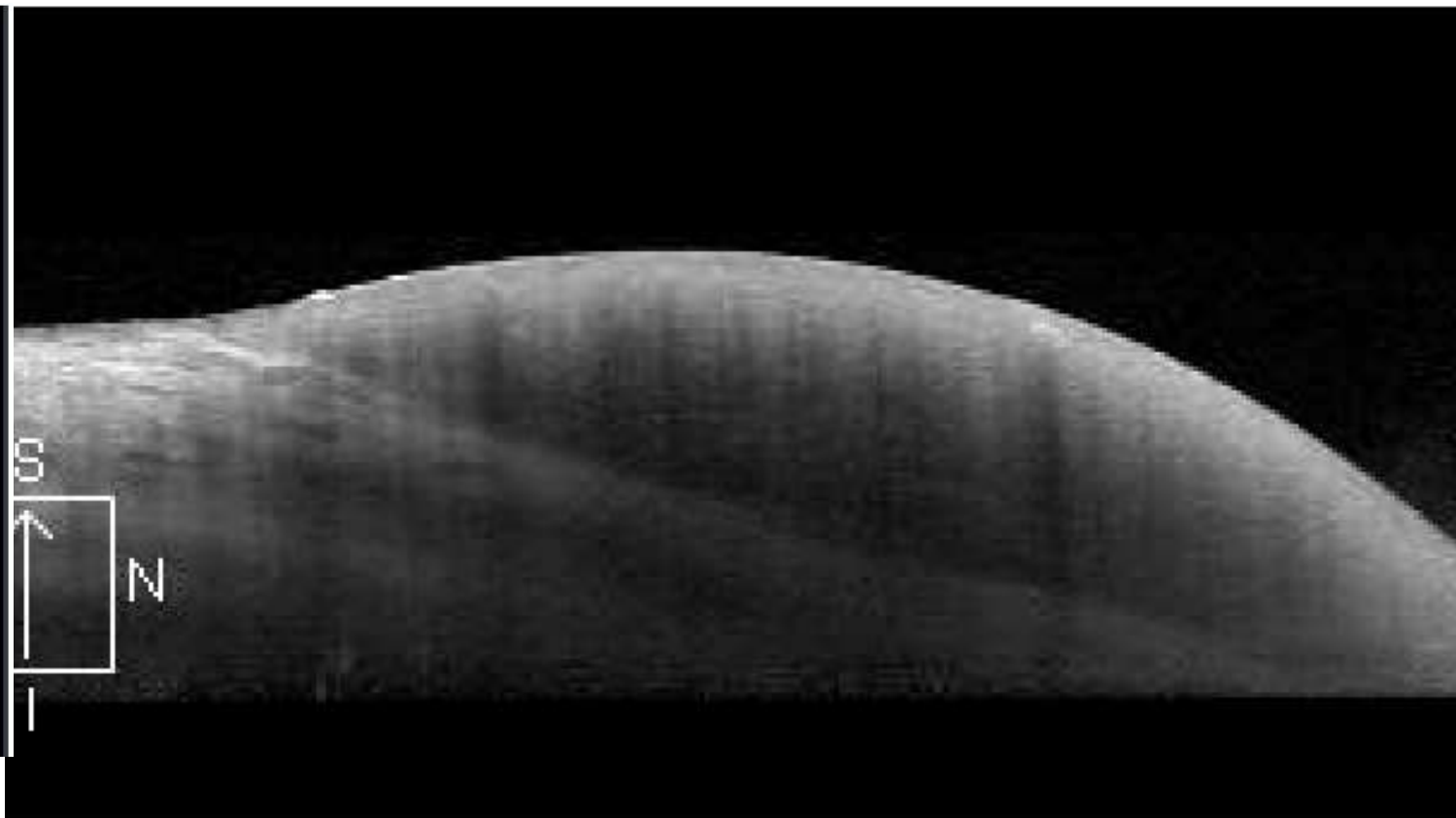
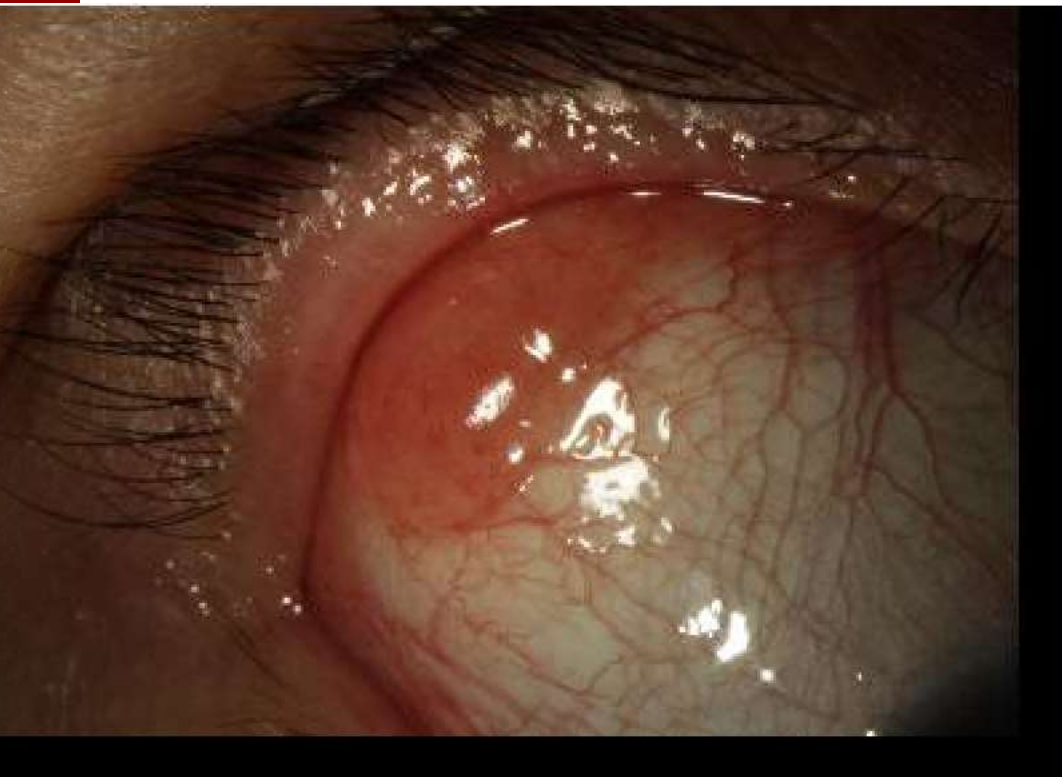

- Salmon pink mass
- Asymptomatic
- Chronic irritation

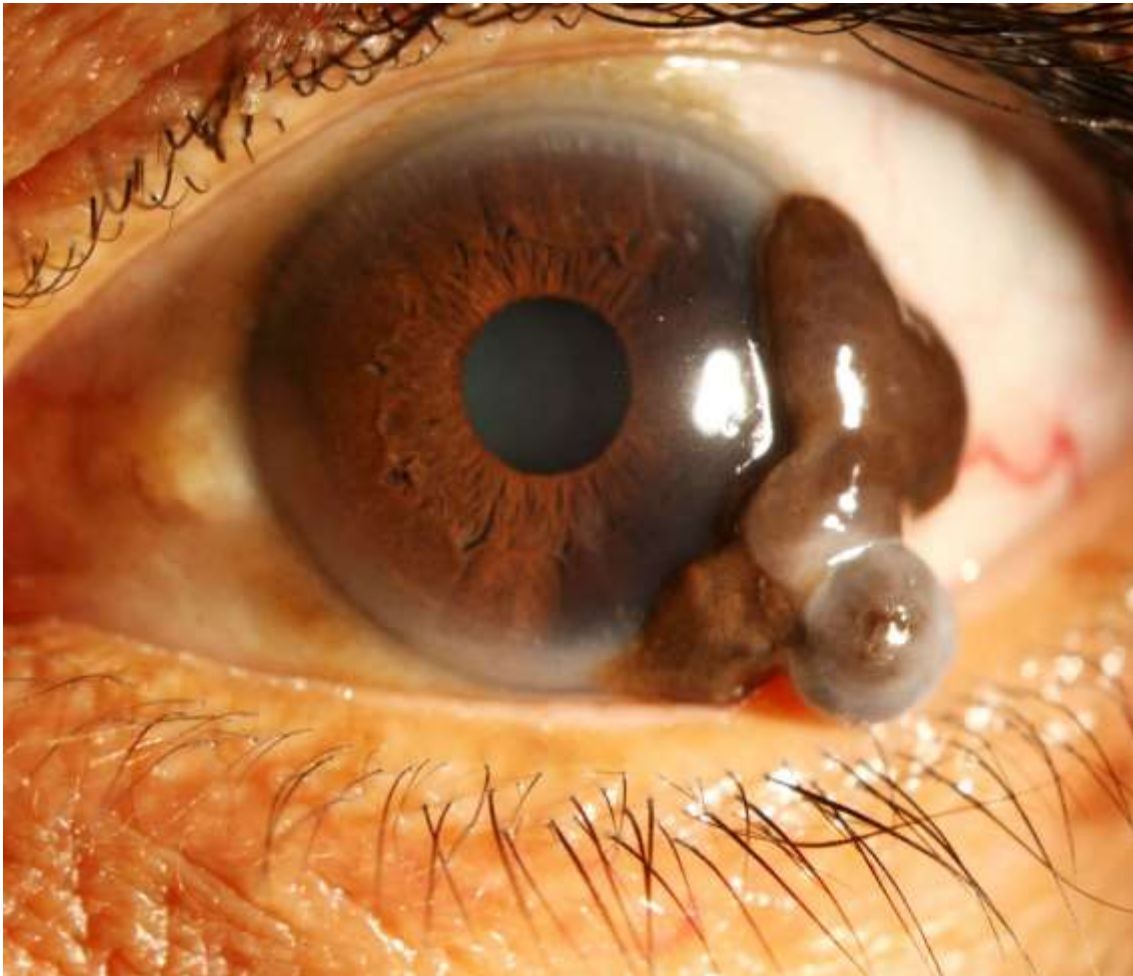


CONJUNCTIVAL LYMPHOMA ON OCT


- INTACT epithelium



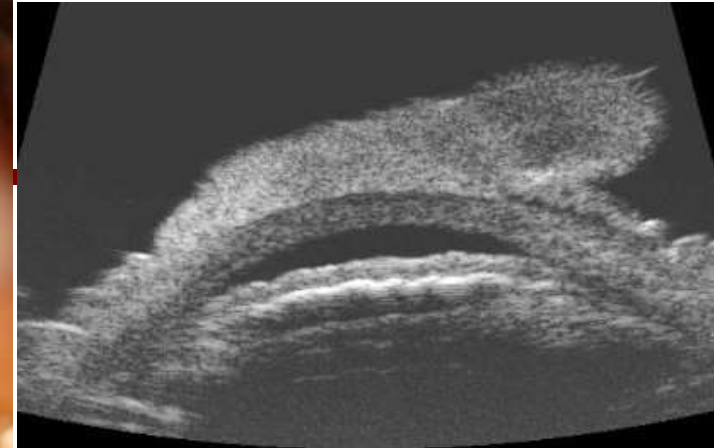
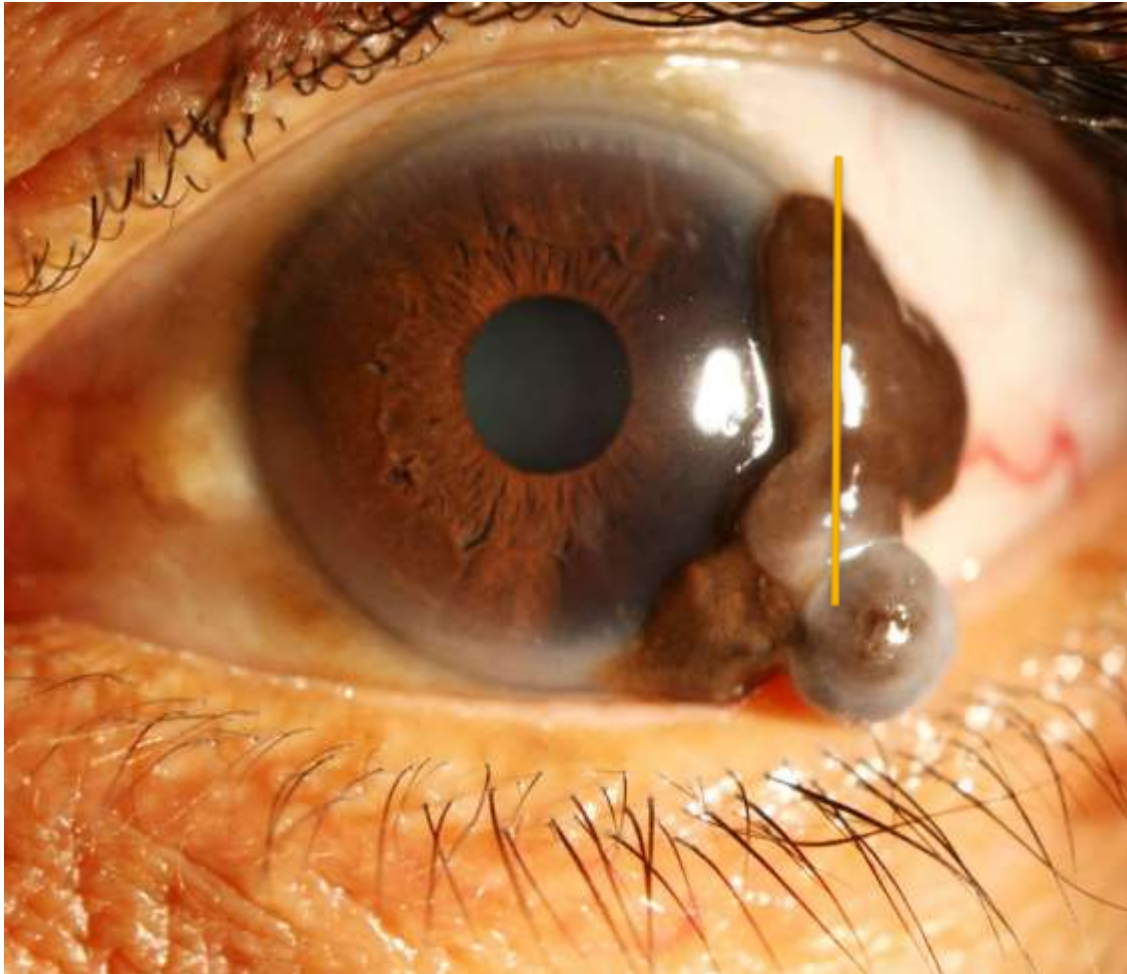
48 YO WITH PIGMENTED LESION



- Farmer with history of foreign body in the past
- Wife says "its growing"
- No change in vision



48 YO WITH PIGMENTED LESION




Spectral Domain
Optical Coherence
Tomography

Depth of invasion

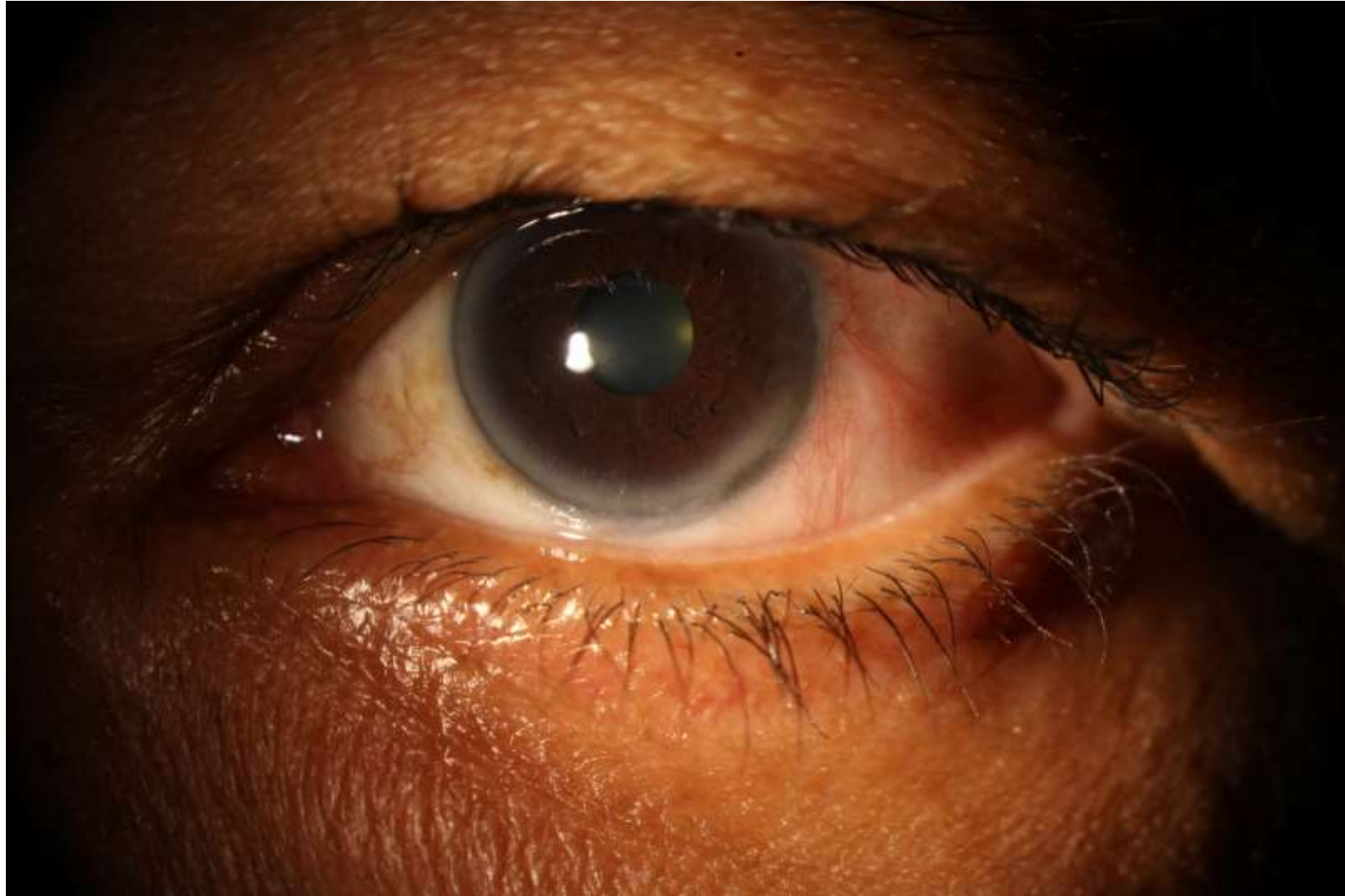




Yiu G, Cummings T, Mruthyunjaya P. JAMA Ophthalmology 2014




48 YO WITH MALIGNANT MELANOMA

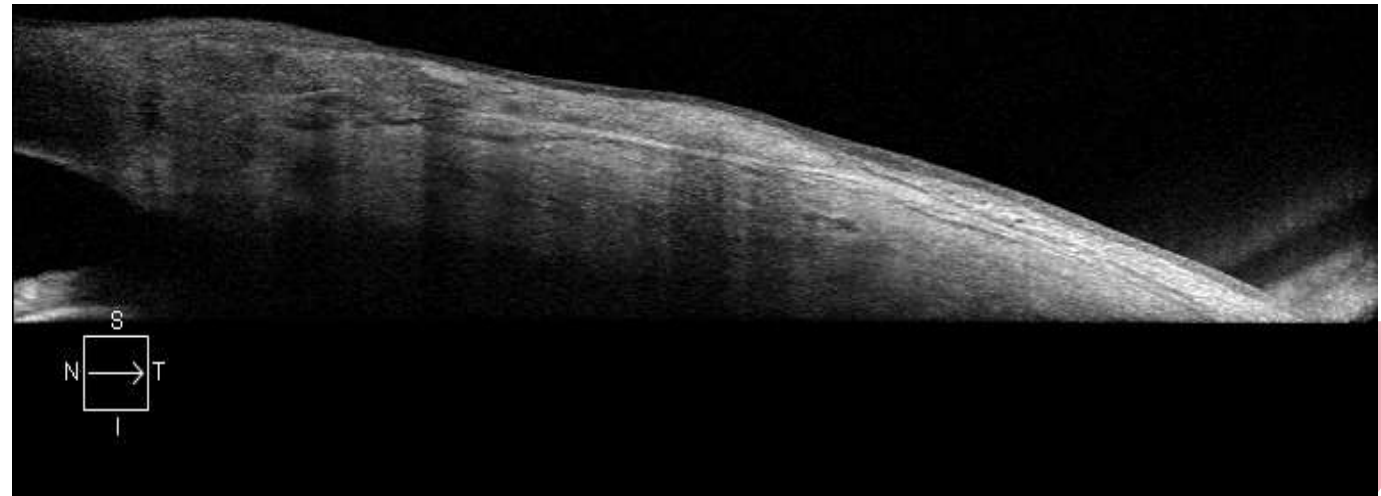
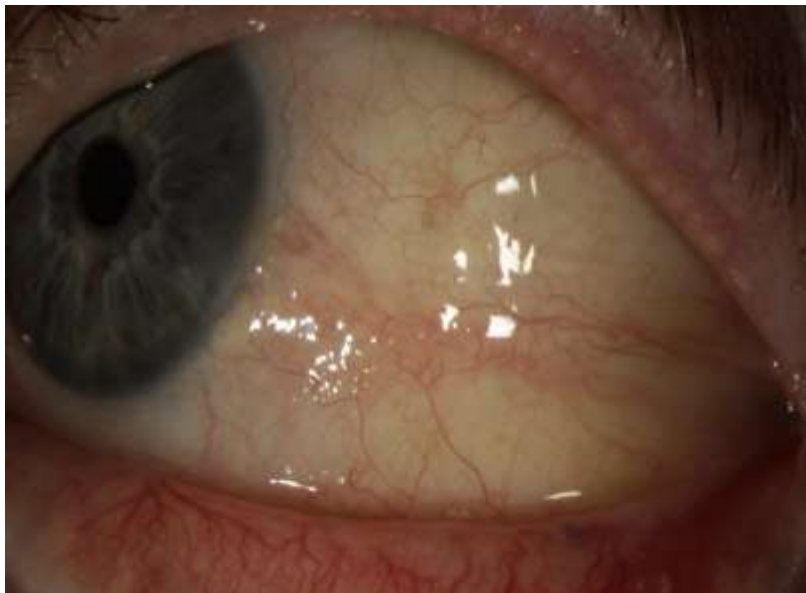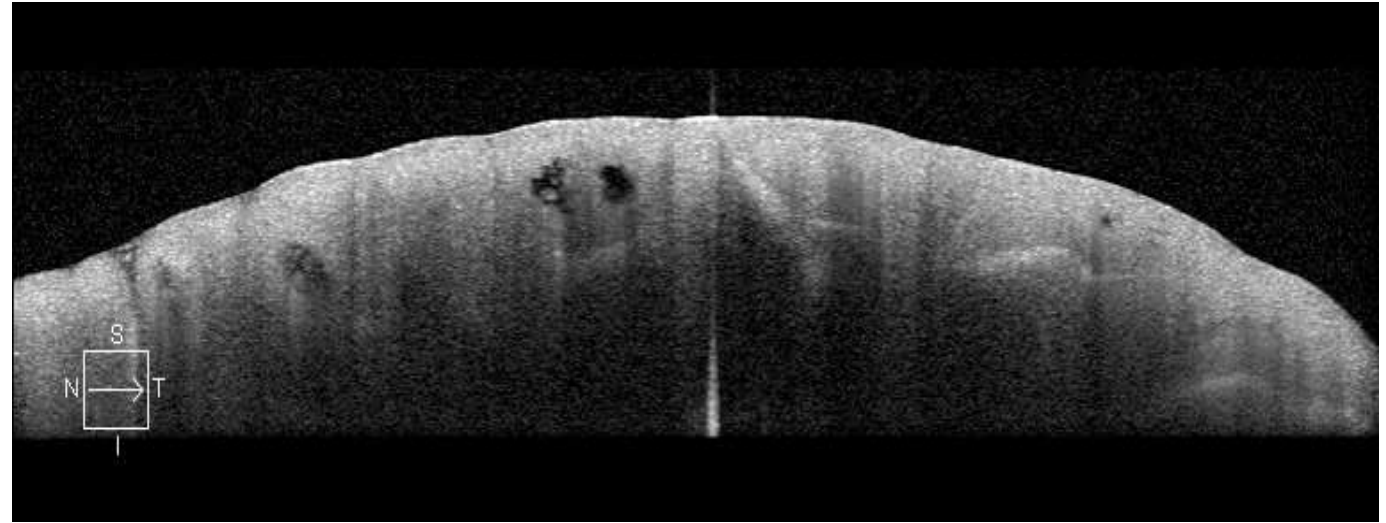

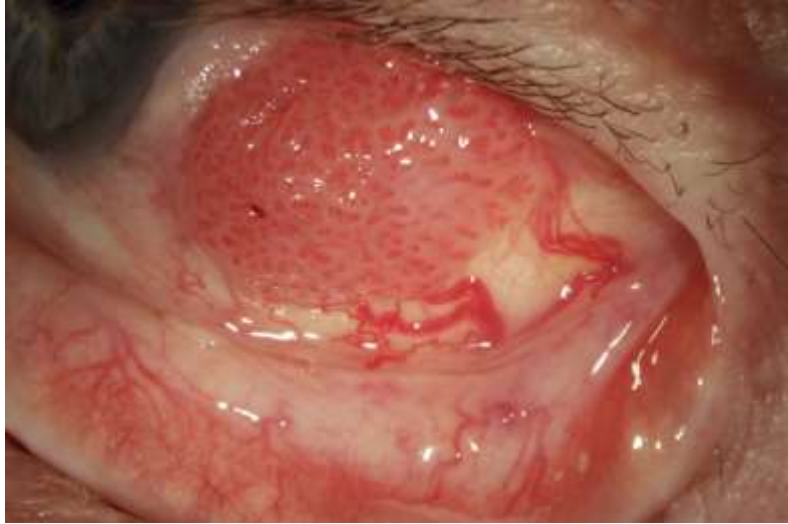
OCT AND ANTERIOR SEGMENT TUMORS: TIPS

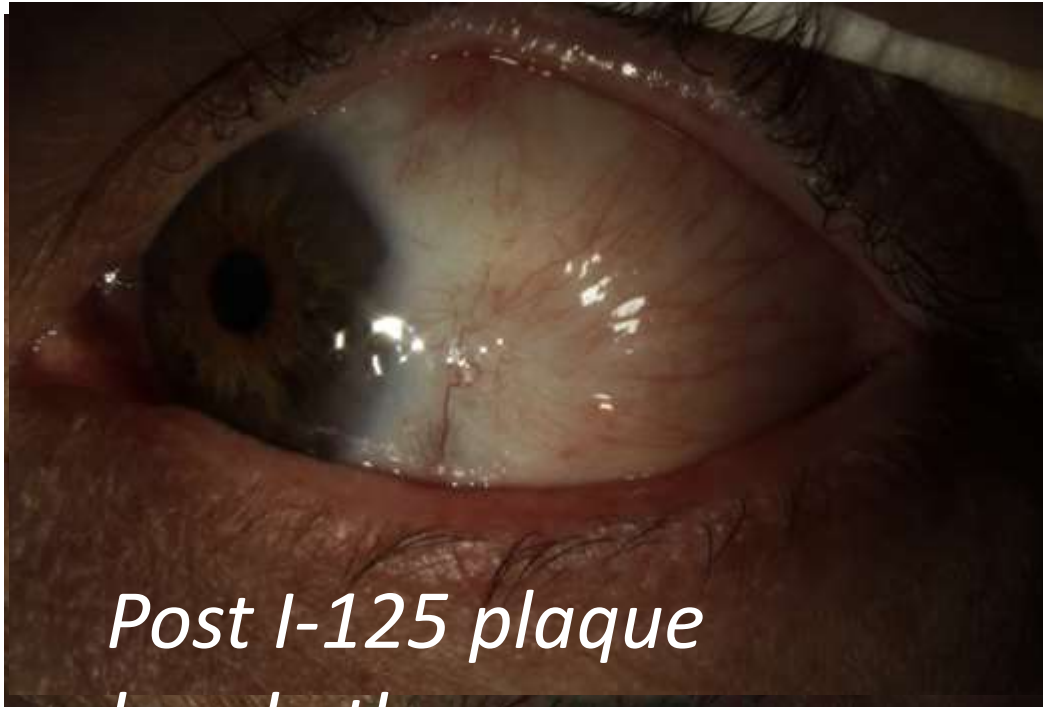
- Look for epithelial layer involvement
 - YES: Squamous neoplasia
 - NO: pingecula, lymphoma
- FULL thickness and cysts
 - NEVUS



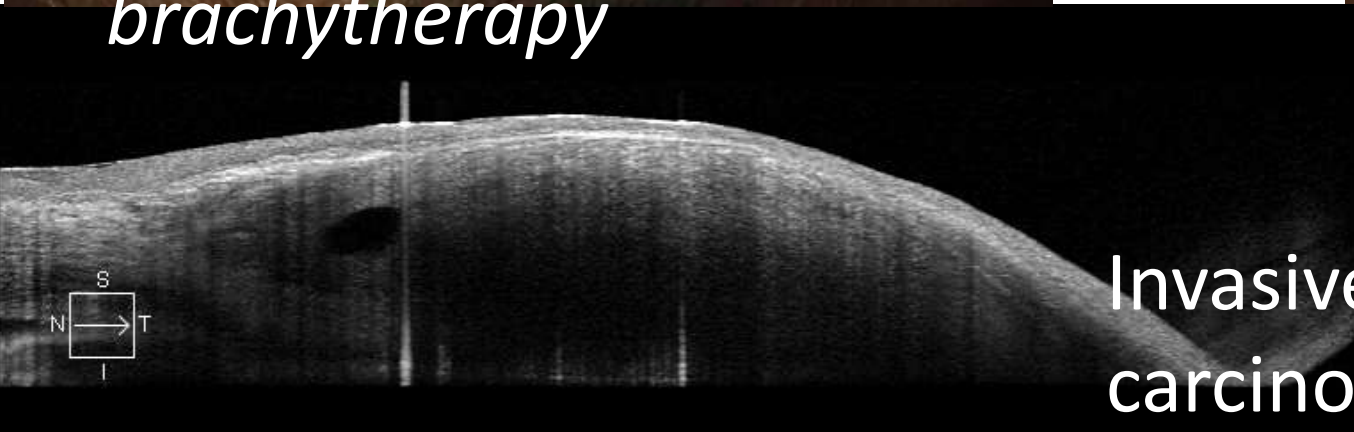
OCT RESPONSE TO THERAPY



OCT GUIDES THERAPY



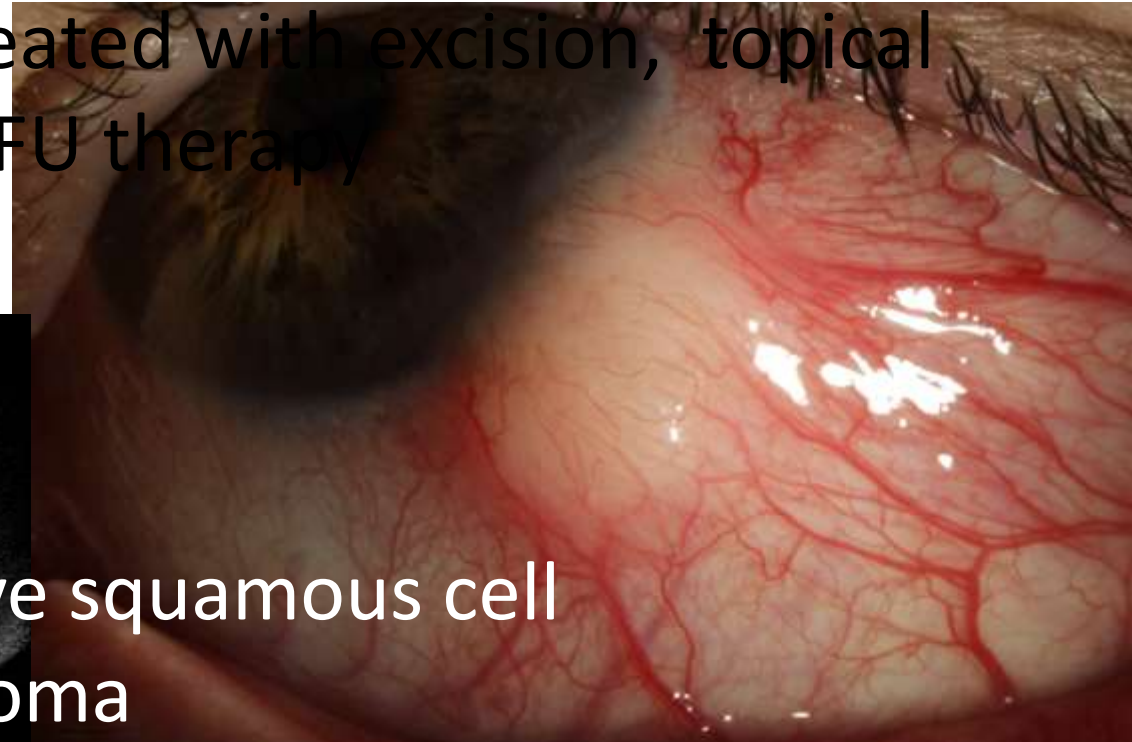
*Post I-125 plaque
brachytherapy*




**Invasive squamous cell
carcinoma**

56 yo wm with history of biopsy proven OSSN then progressed to SCC


- treated with excision, topical 5-FU therapy






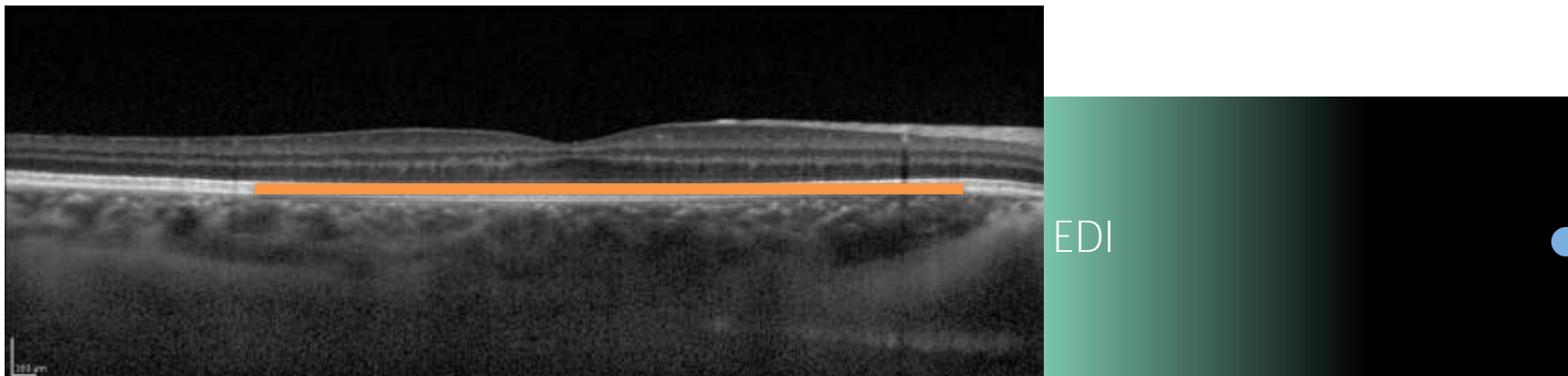
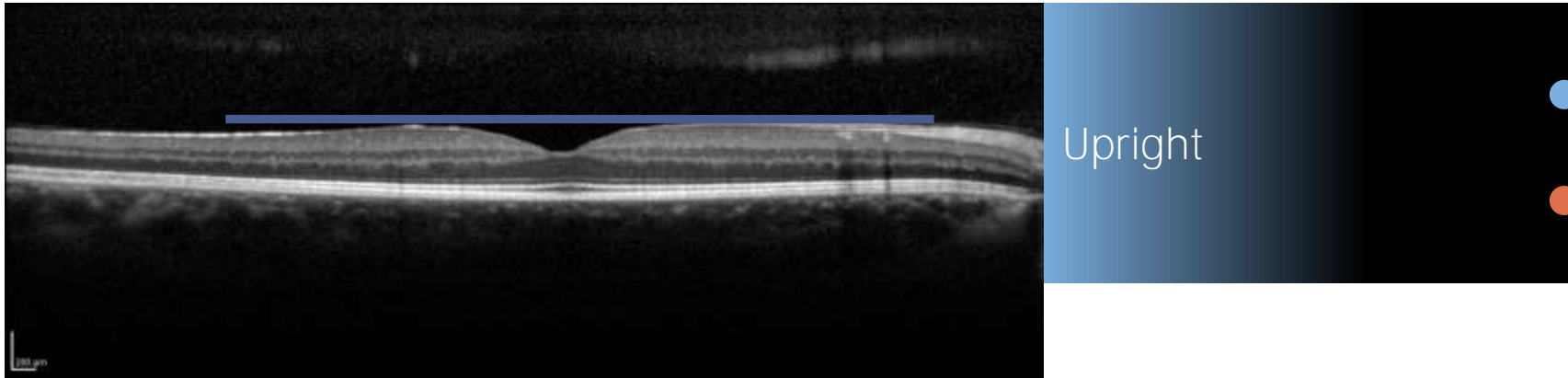
OCT OF POSTERIOR OCULAR TUMORS

- **Identify the choroidal component of the lesion.**
 - Thickness
- **Demonstrates surface features:**
 - presence of sub retinal fluid
 - RPE atrophy
 - DRUSEN overlying the lesion which may suggest chronicity
 - Lipofuscin deposits
 - intraretinal fluid collections

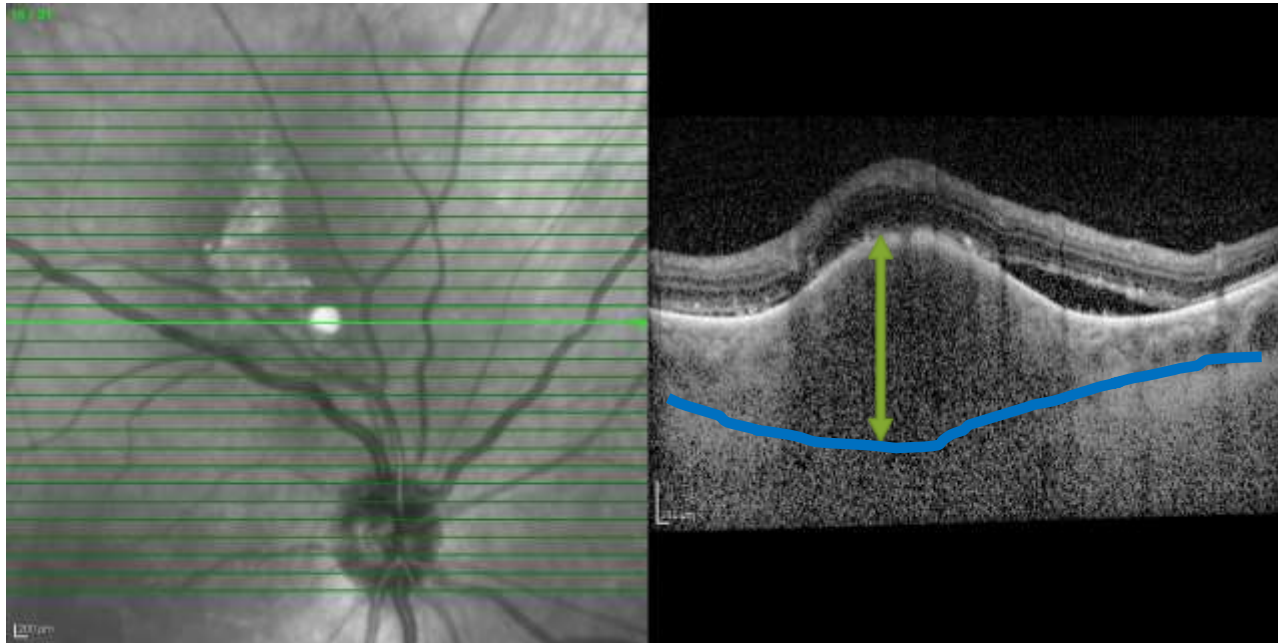


ENHANCED DEPTH OCT: IMPROVES IMAGING

- Reference point for optimal image capture




ENHANCED DEPTH IMAGING OCT: THICKNESS



- Limitations:
 - tumors typically <2.5mm thick
 - Inconsistent imaging of SCJ
 - Tumor base measurements

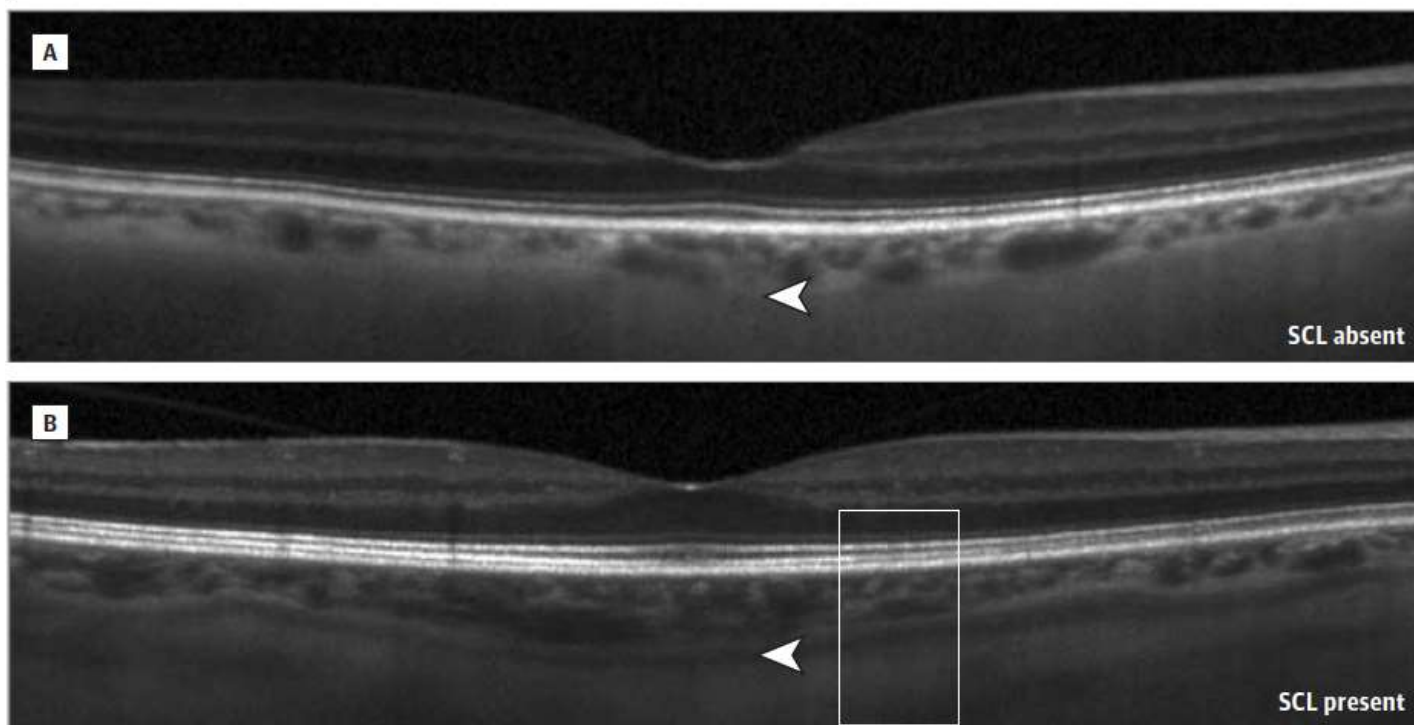
Shah et al. 2014; Dimerci et al. 2015



Characterization of the Choroid-Scleral Junction and Suprachoroidal Layer in Healthy Individuals on Enhanced-Depth Imaging Optical Coherence Tomography

Glenn Yiu, MD, PhD; Paula Pecen, MD; Neeru Sarin, MD; Stephanie J. Chiu, BSE; Sina Farsiu, PhD; Prithvi Mruthyunjaya, MD; Cynthia A. Toth, MD

JAMA Ophthalmology February 2014 Volume 132, Number 2



- AREDs2 SDOCT study
- CSJ noted in 44% of eyes
- Impacts choroidal thickness measurements
 - Age



CHOROIDAL NEVUS

Height:
flat to 2.0mm



No Subretinal
fluid



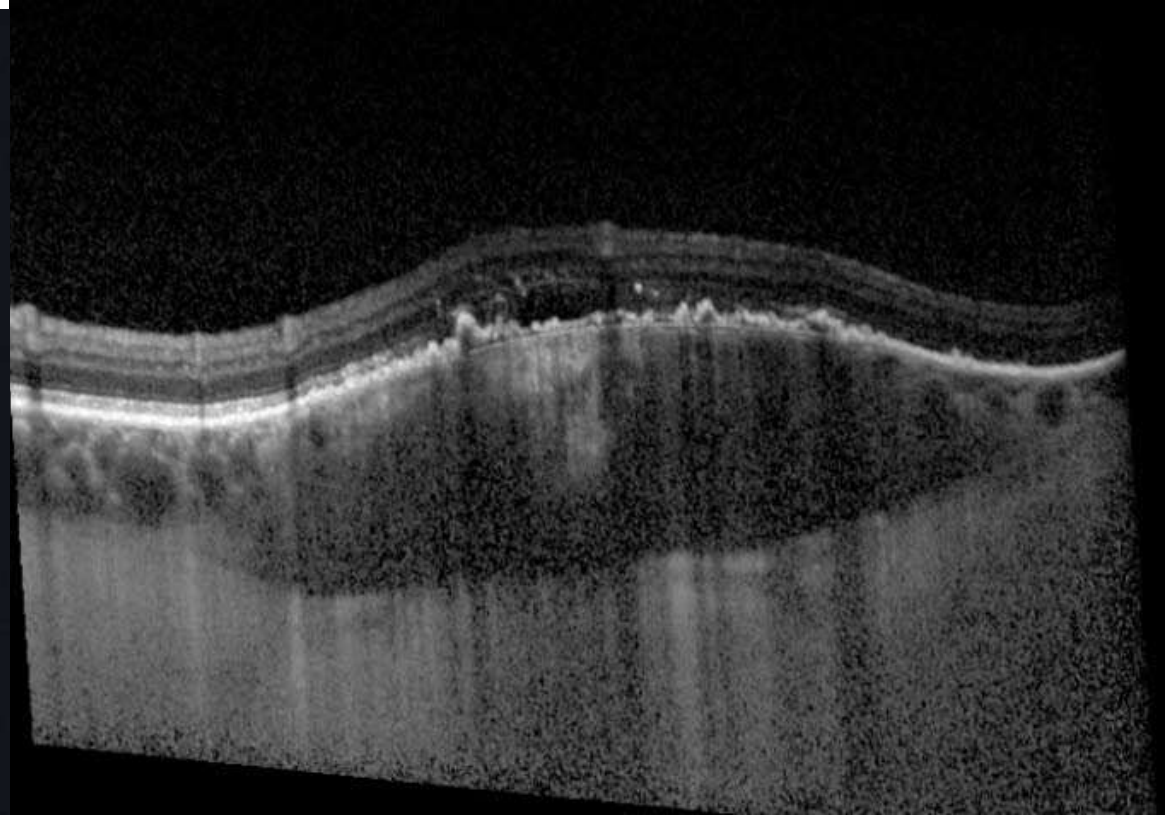
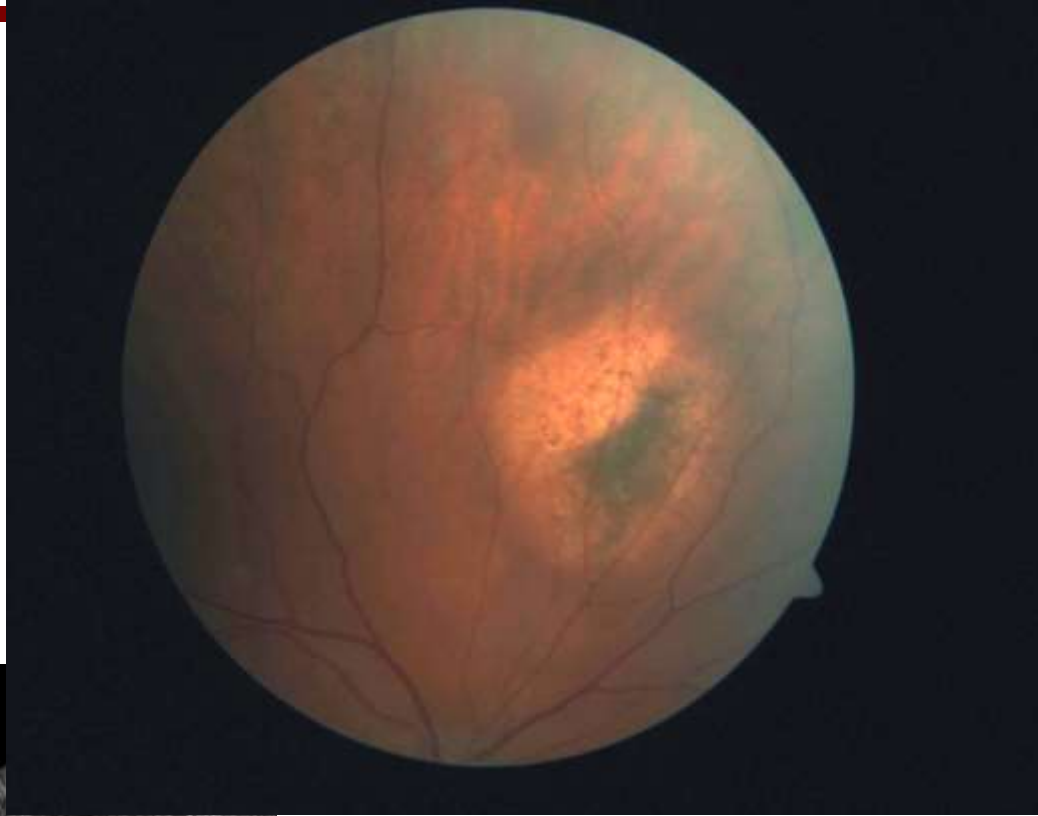Drusen



Serial exams, photographs
observe




OCT OF CHOROIDAL NEVUS




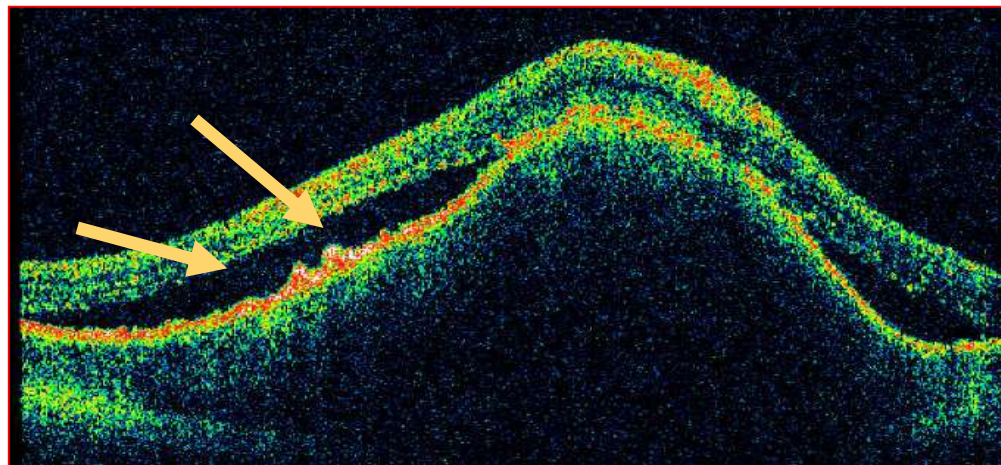
0.88mm
4.27mm

Compaction of choriocapillaris
Thickness variable
Surface features



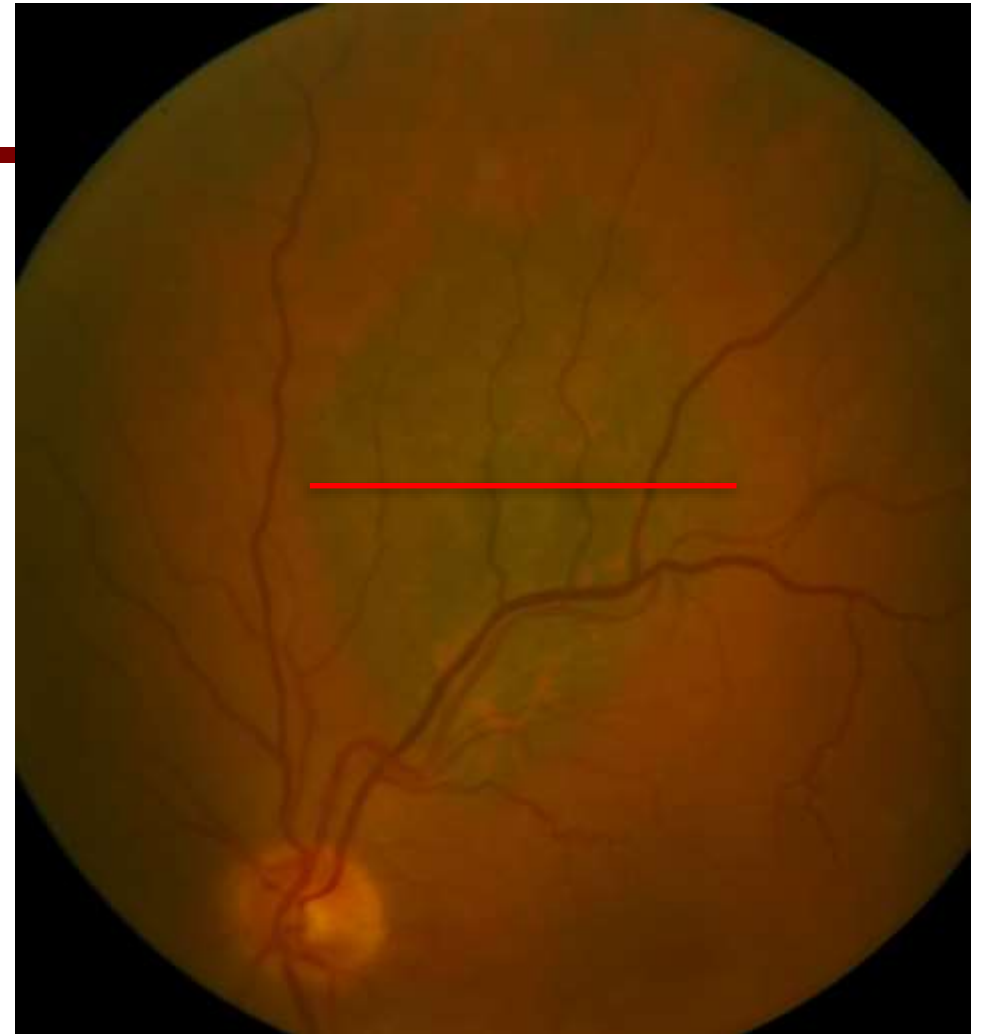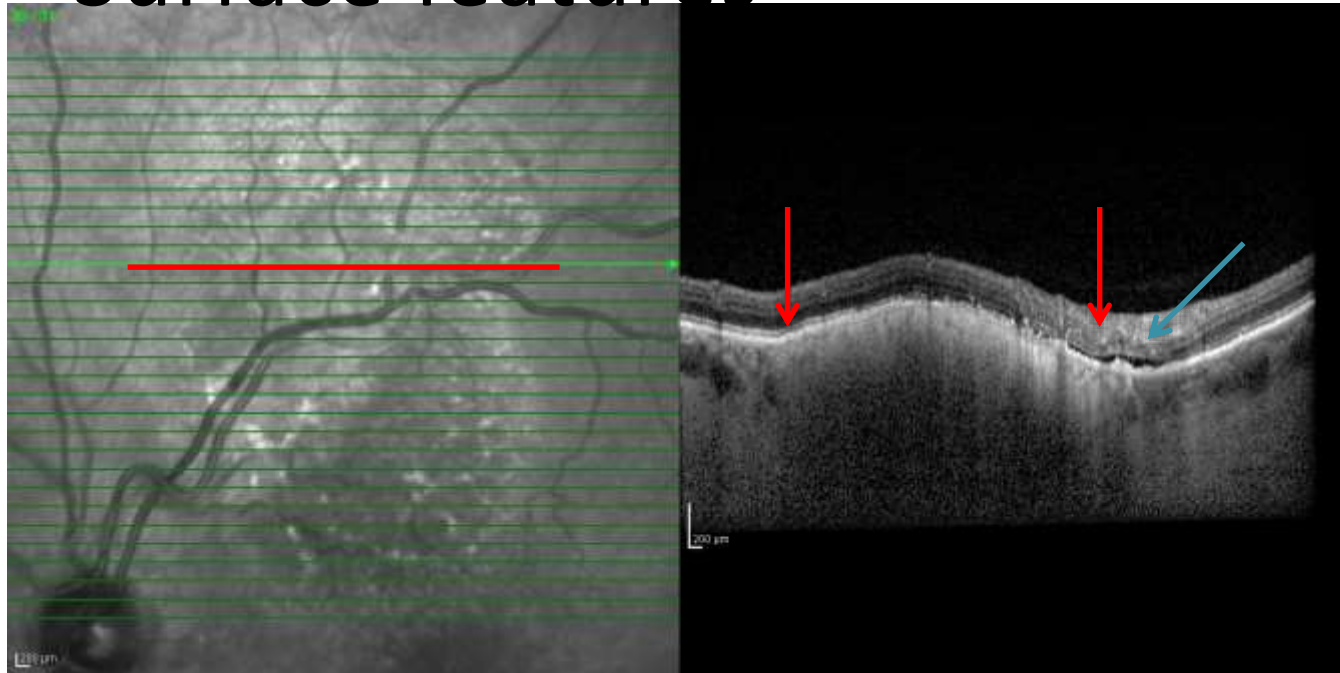
OCT IDENTIFIES SURFACE ALTERATIONS

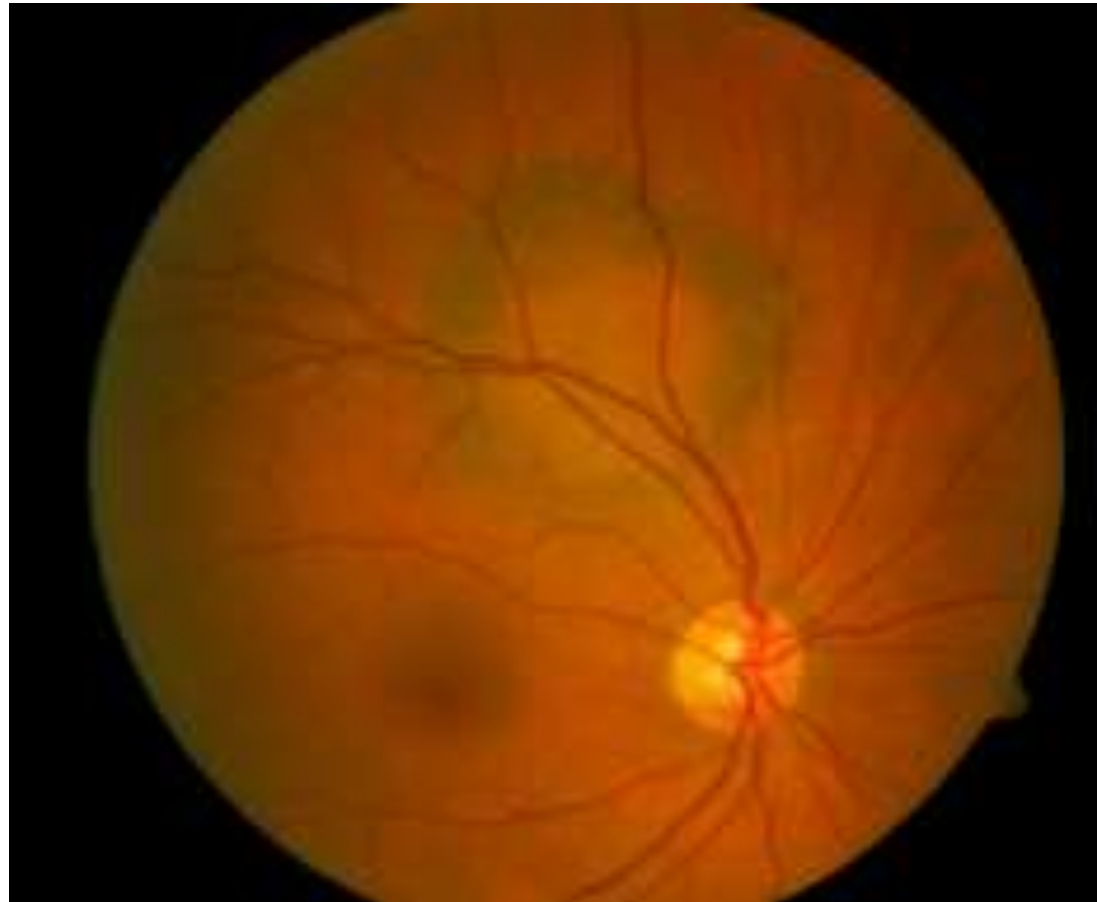- intraretinal fluid collections
- retinal thickening
- RPE alterations
- sub-retinal deposits
- sub-retinal fluid




OCT OF CHOROIDAL NEVUS

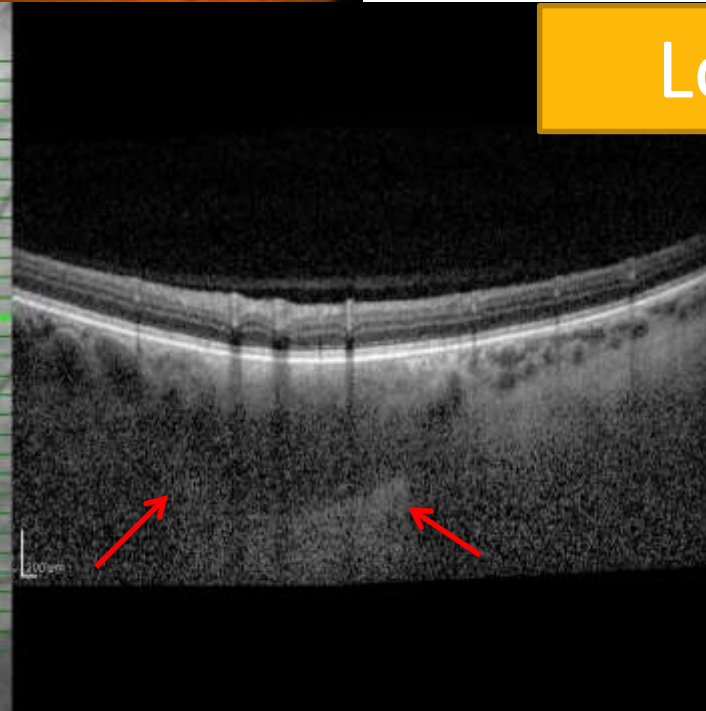
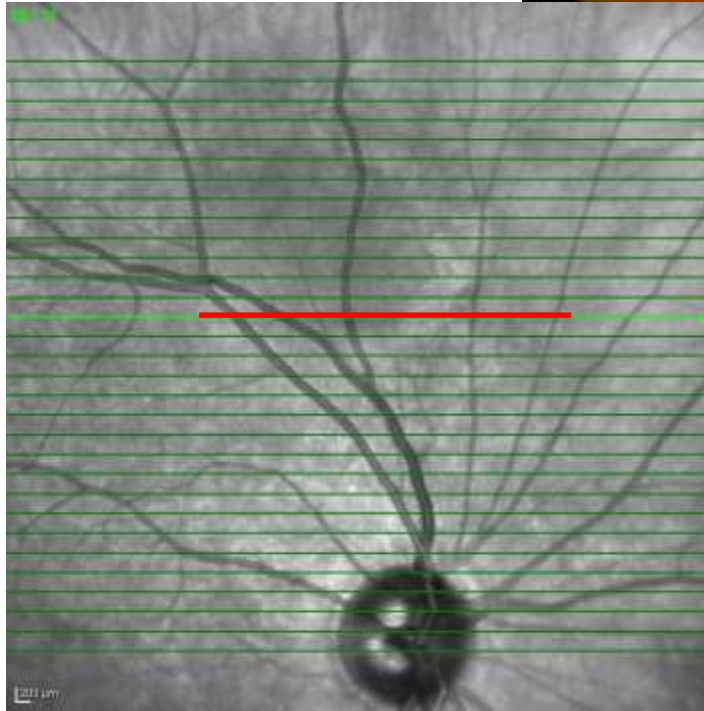
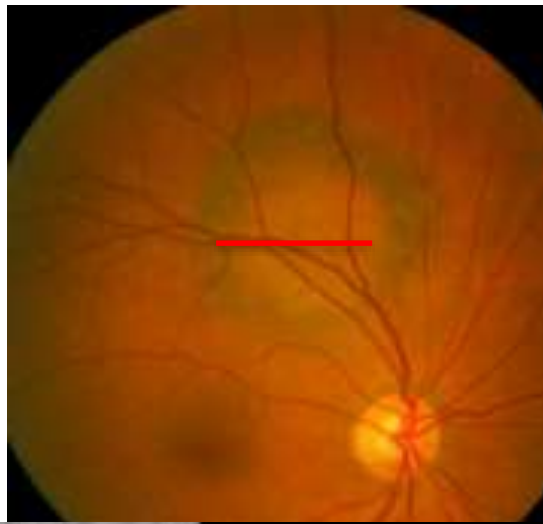
- Compaction of choriocapillaris
- Surface features





- 60 yo female
- Asymptomatic
- Inverted halo peripapillary lesion
- Minimally elevated on exam and ultrasound
- Nevus? Melanoma?



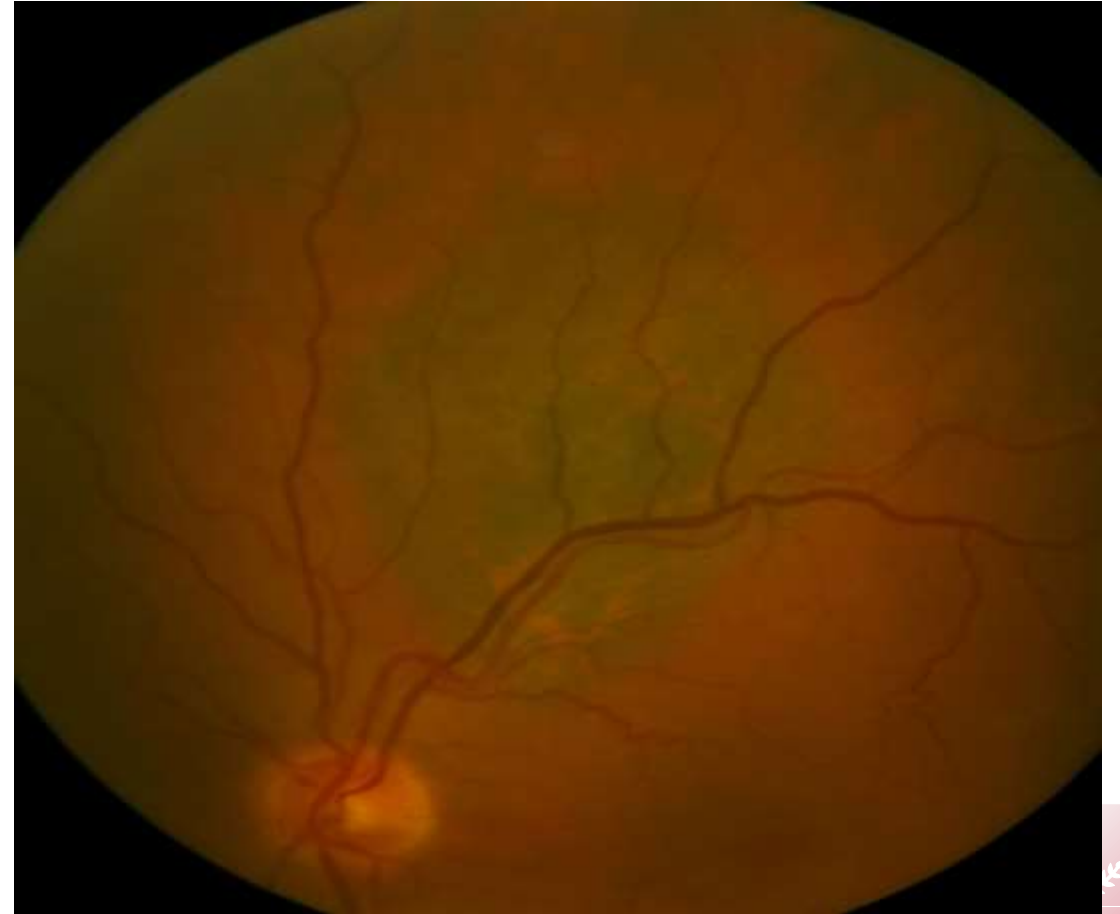

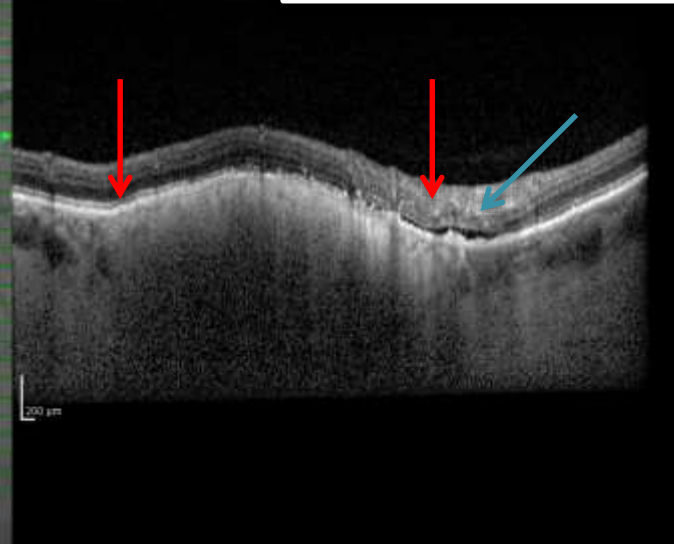
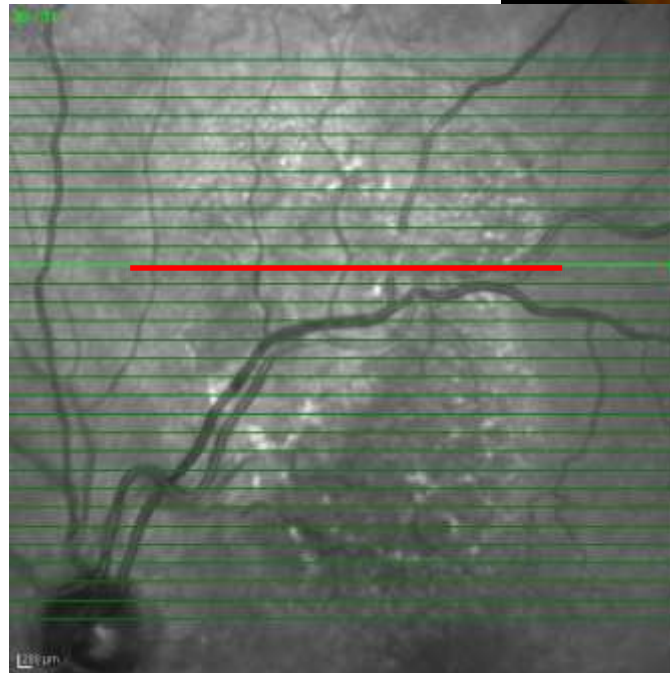
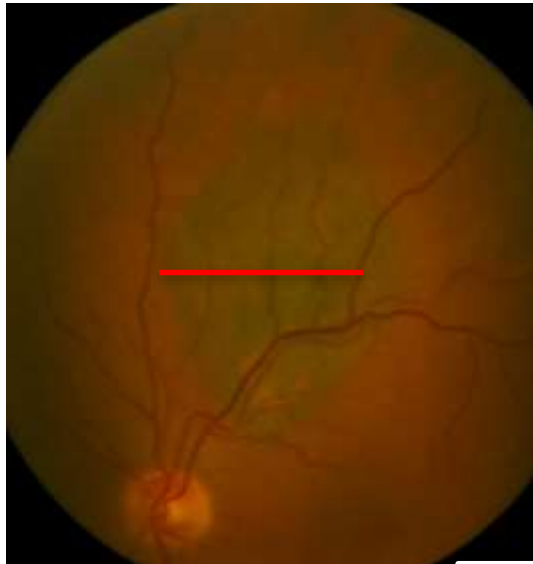Low Suspicion




- 55 yo male
- Visual symptoms
- Peripapillary lesion
- No clinical or ultrasound elevation

- NEVUS? MELANOMA?





Higher Suspicion

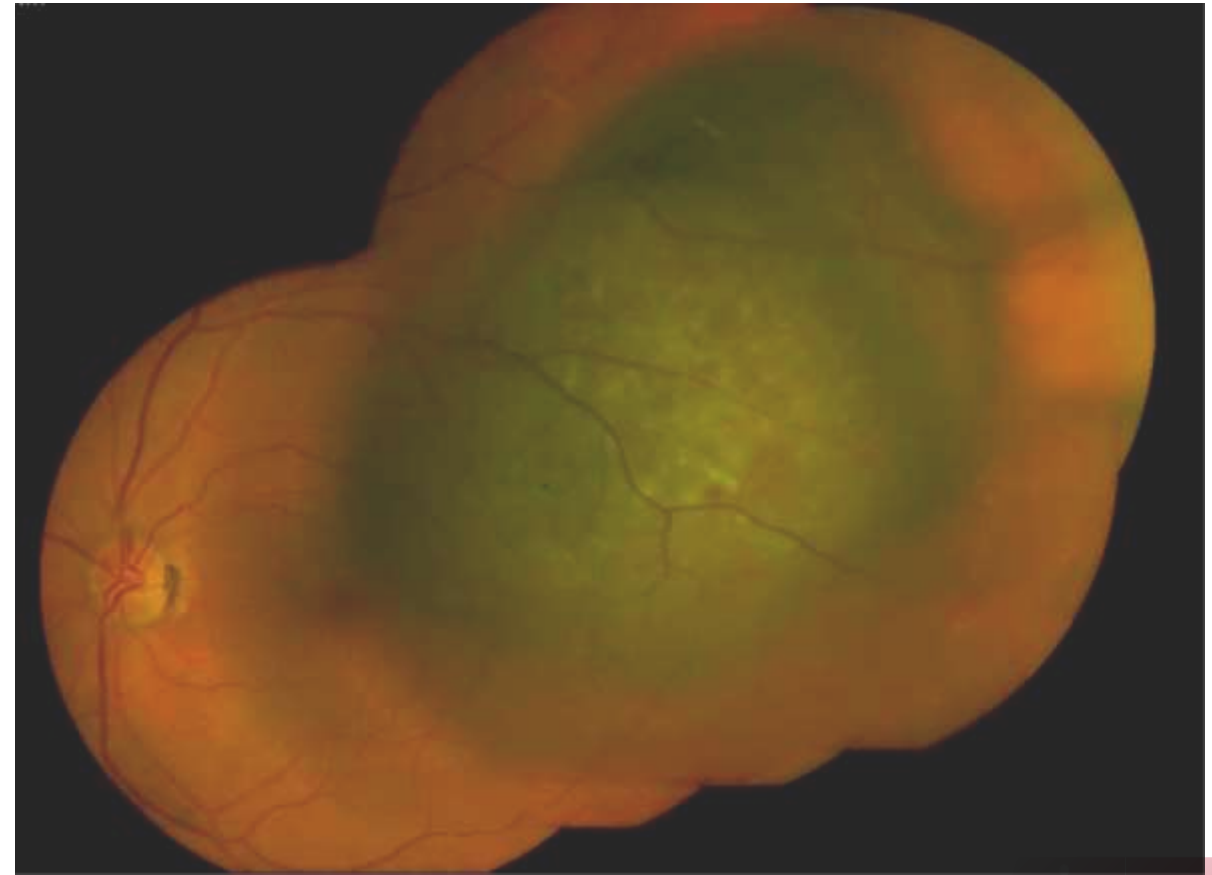


CHOROIODAL MELANOMA


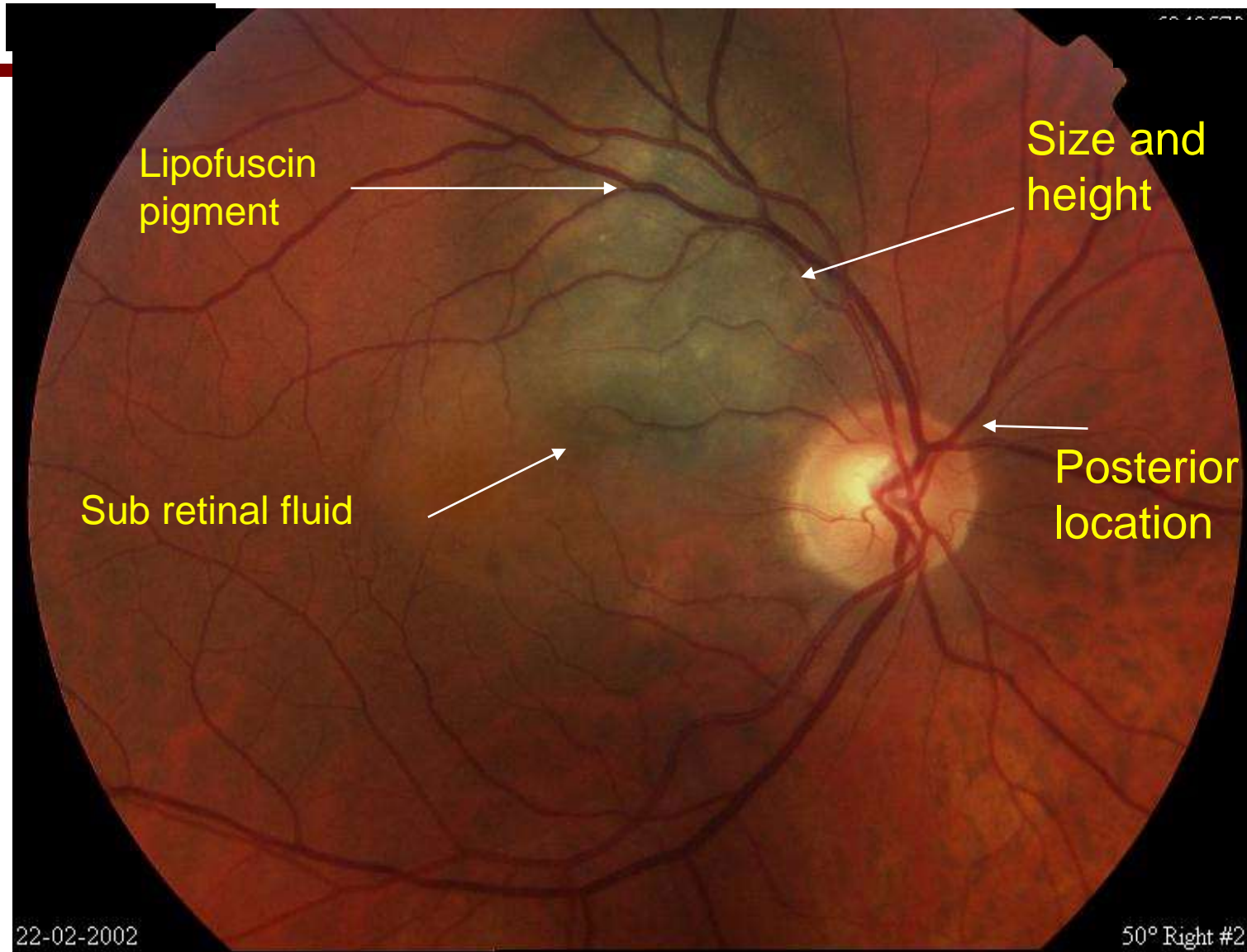
Most common primary ocular malignancy

Starts from a nevus

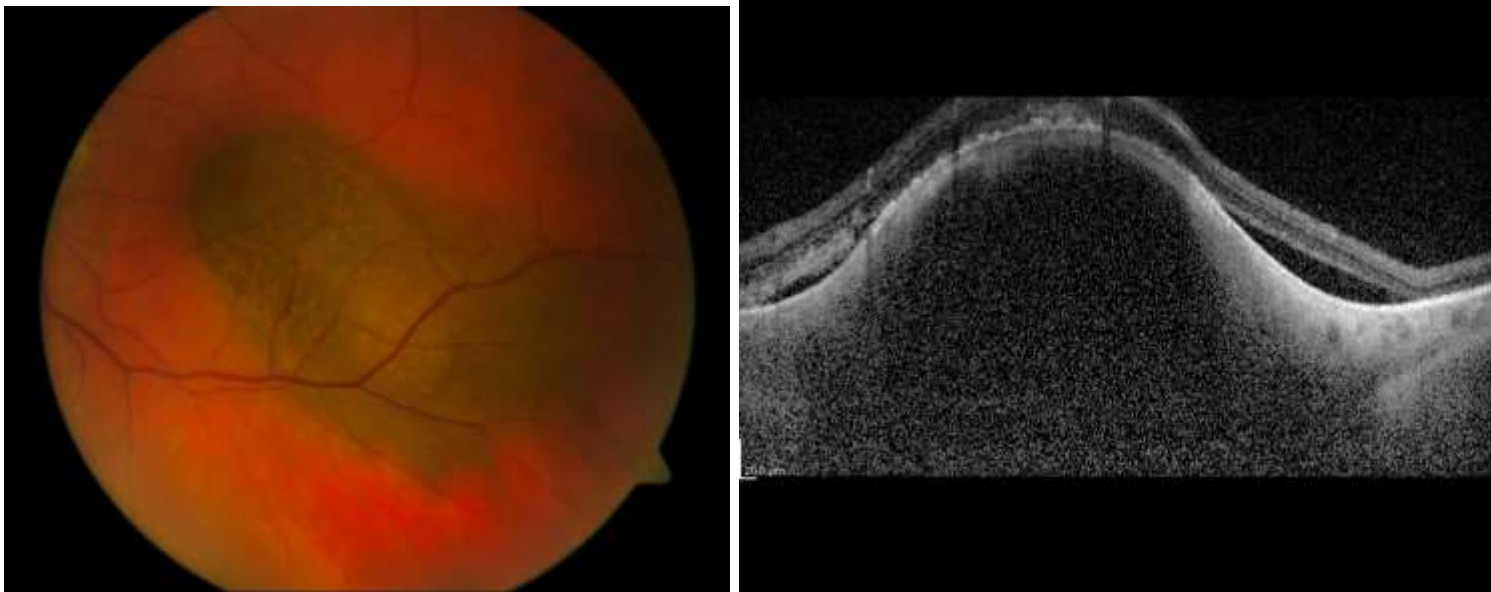
45% of patients develop metastatic disease



CHOROIDAL MELANOMA




OCT OF CHOROIDAL MELANOMA

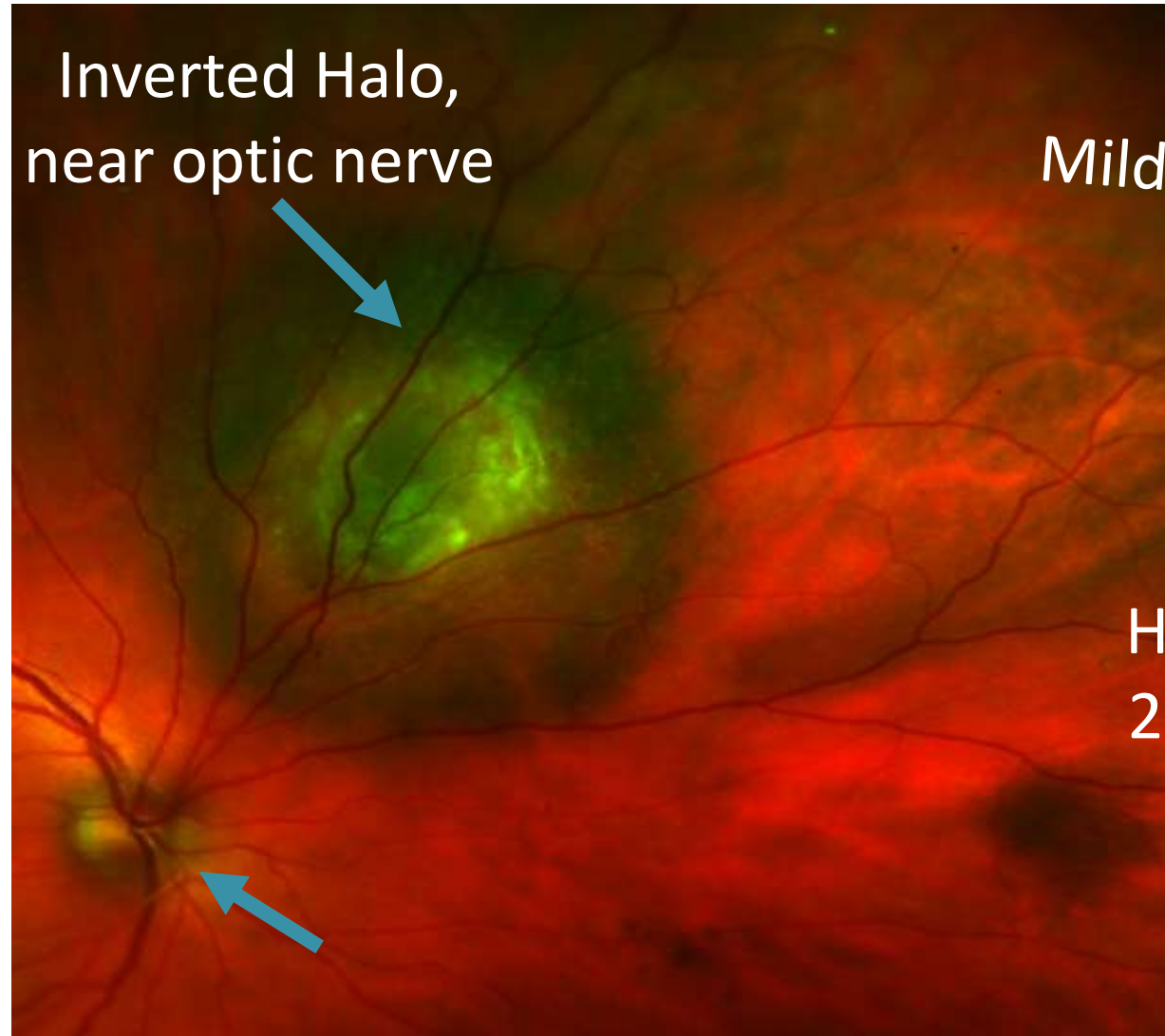


Choroidal melanoma

- Greater height than nevus
- Subretinal fluid
- Smooth domed appearance



INDETERMINATE CHOROIODAL LESION




Mild Subretinal
fluid

A cross-sectional OCT scan of the retina. A blue arrow points to a small, dark space between the retinal layers, labeled 'Mild Subretinal fluid'.


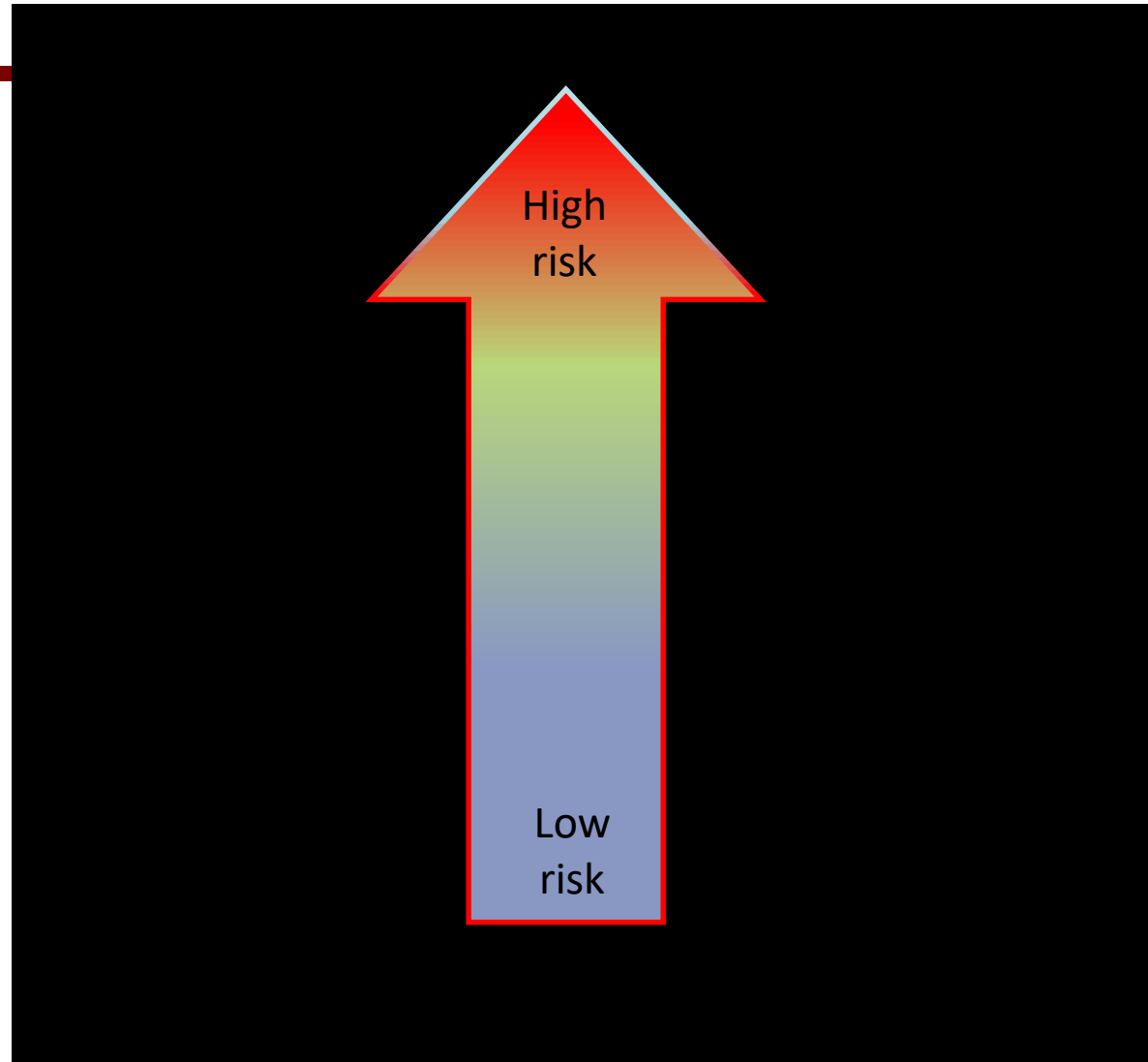
Height:
2.5mm

A cross-sectional OCT scan of the retina. A blue arrow points to a dark, dome-shaped lesion. The text 'Height: 2.5mm' is written next to it.

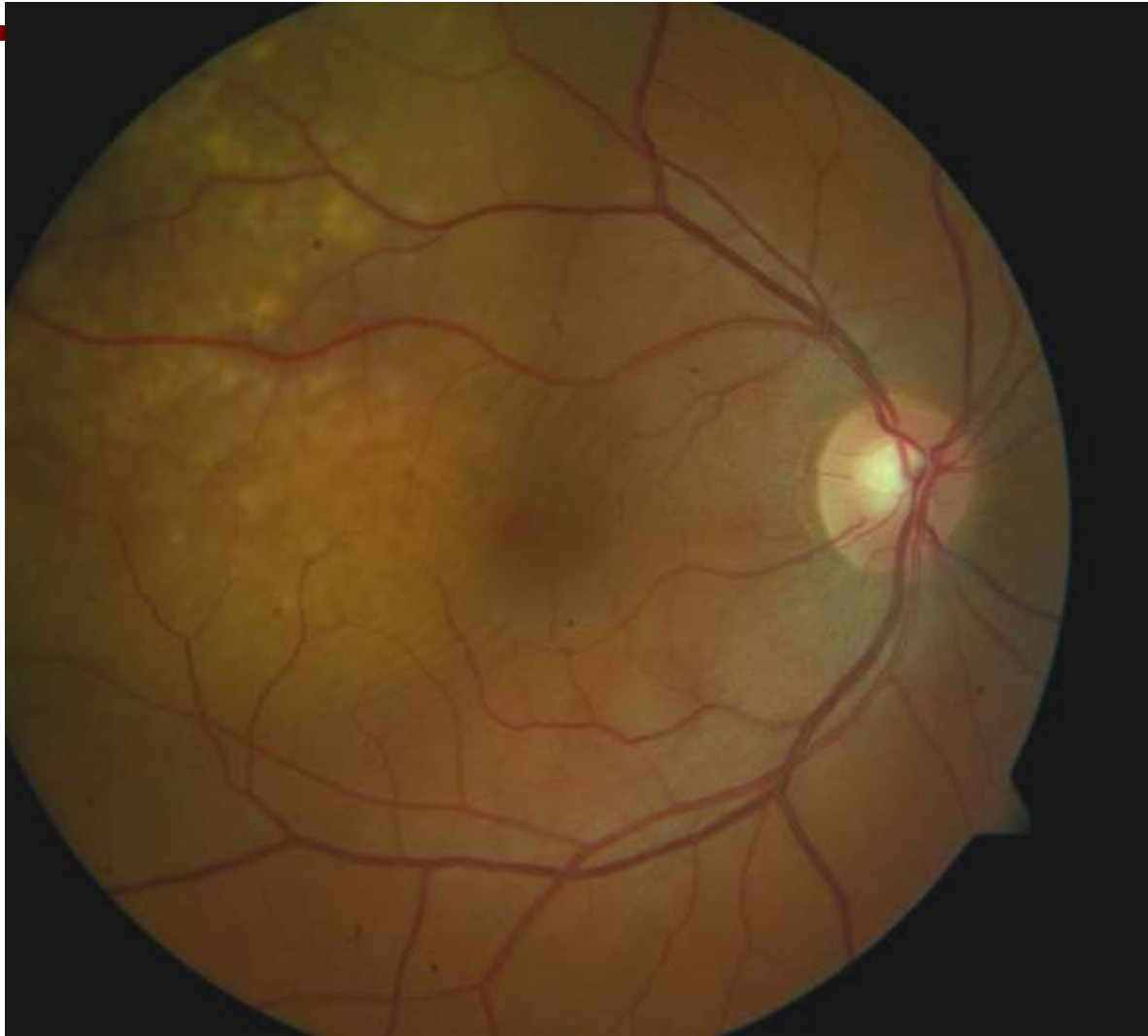

NOT ALL TUMOR FLUID IS THE SAME...

- **Active tumor exudation**
 - SRF along tumor base
 - “shaggy” photoreceptors
 - Acute hyper FAF changes
- **Chronic RPE alterations**
 - Pigment epithelial detachment
 - Drusen
 - Apical subretinal fluid
 - RPE atrophy/metaplasia
- **Intraretinal fluid collections**
 - Chronic RPE dysfunction




IT BEGINS..


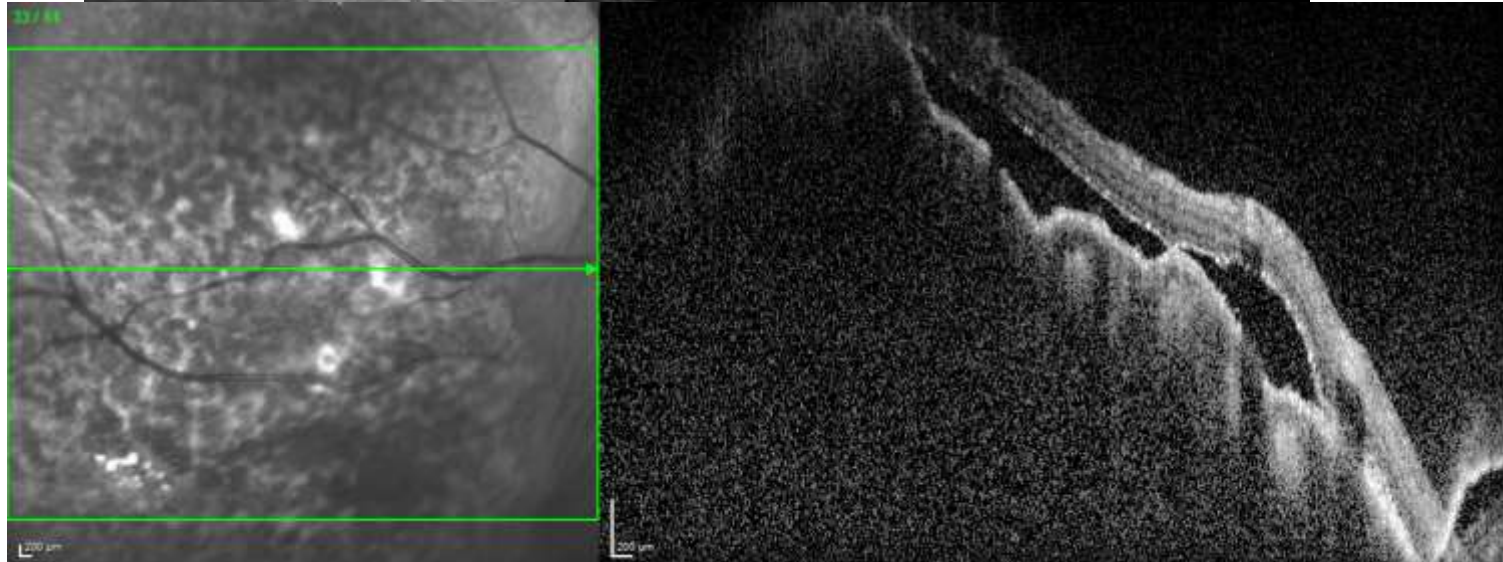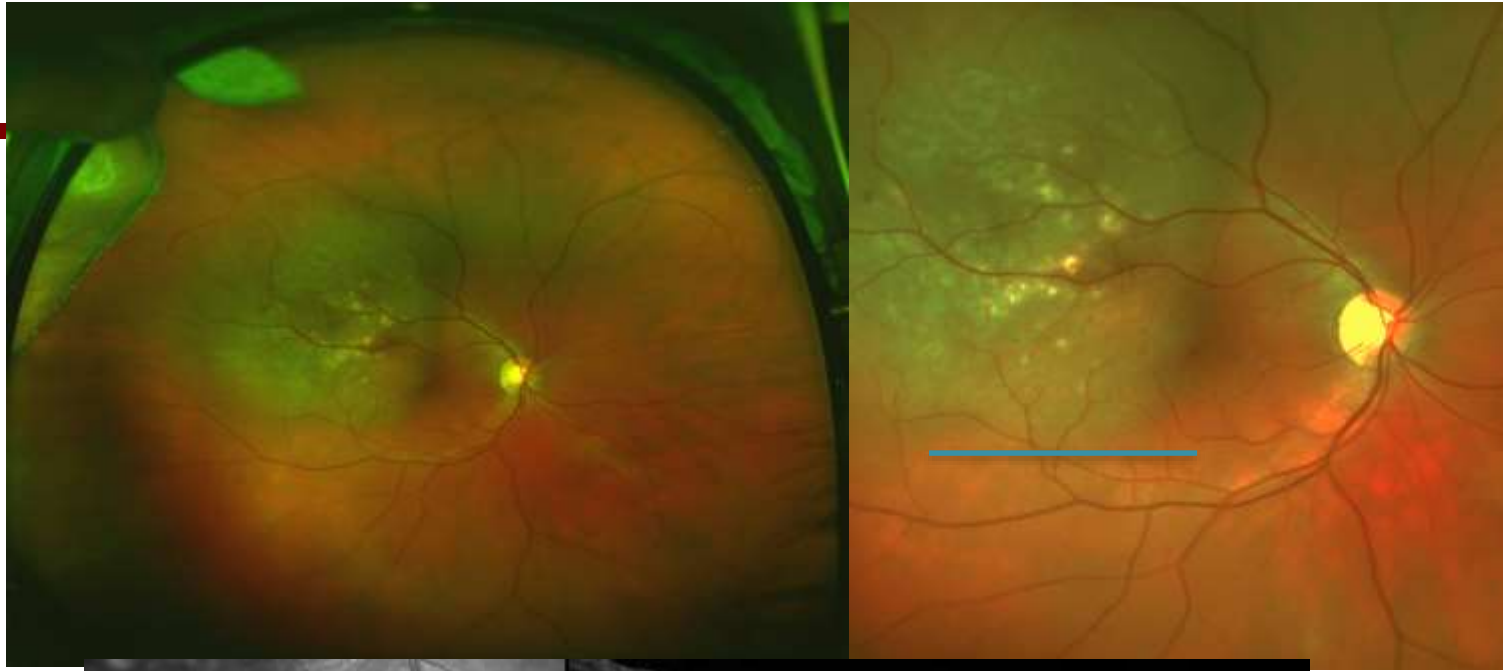


45 yo white male with acute vision loss in the right eye

PMH: healthy, non smoker


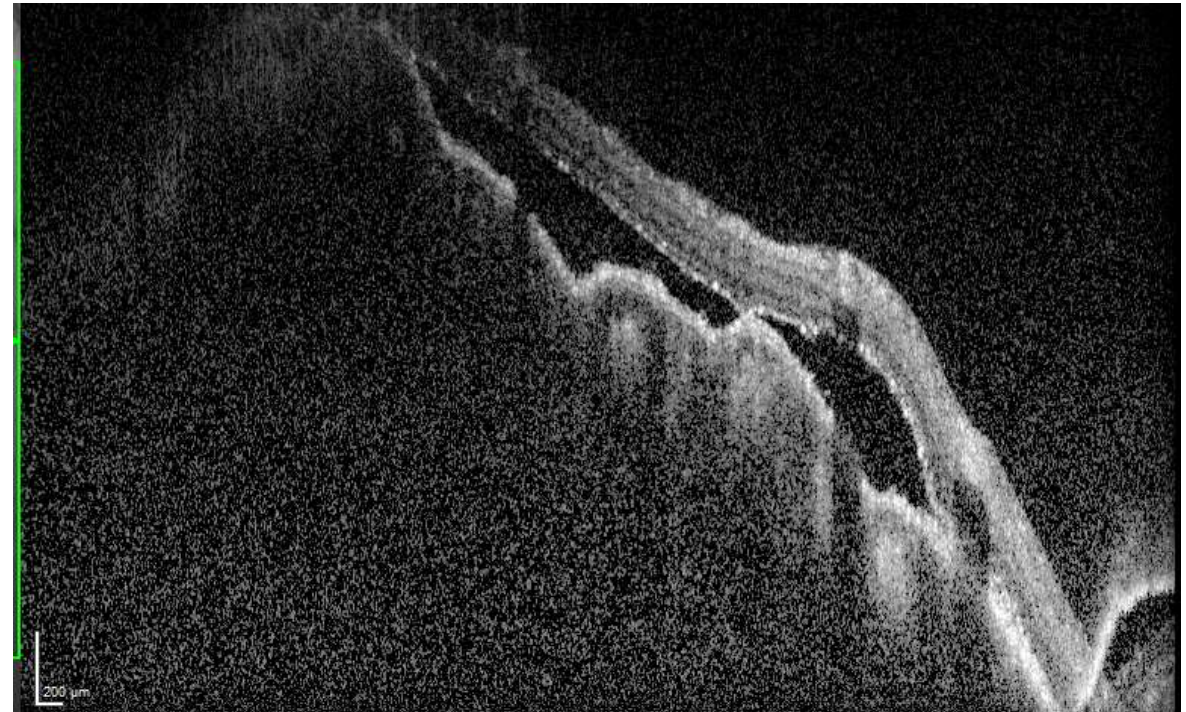
Family history: no malignancy




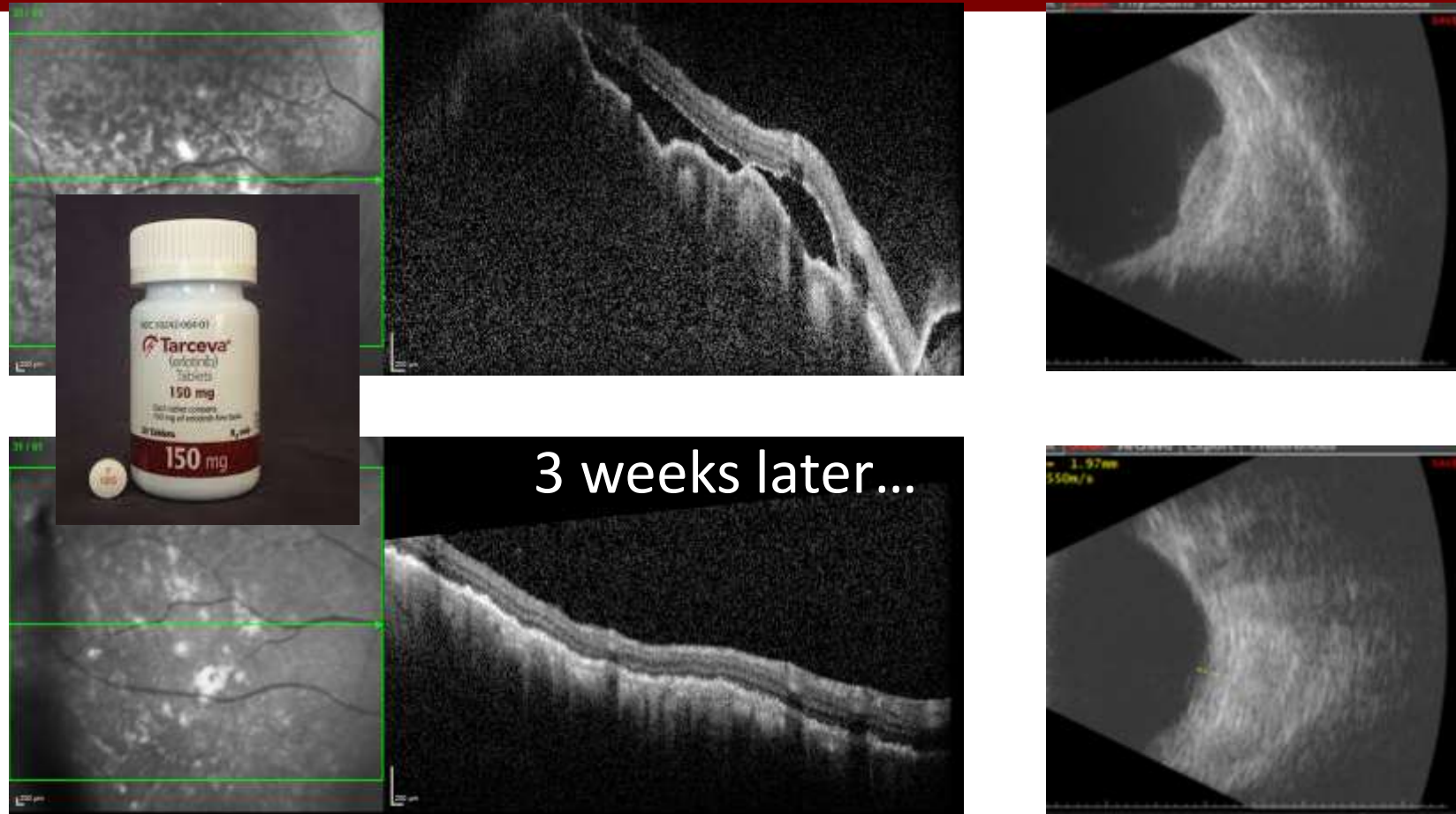


OCT OF CHOROIODAL METASTASIS

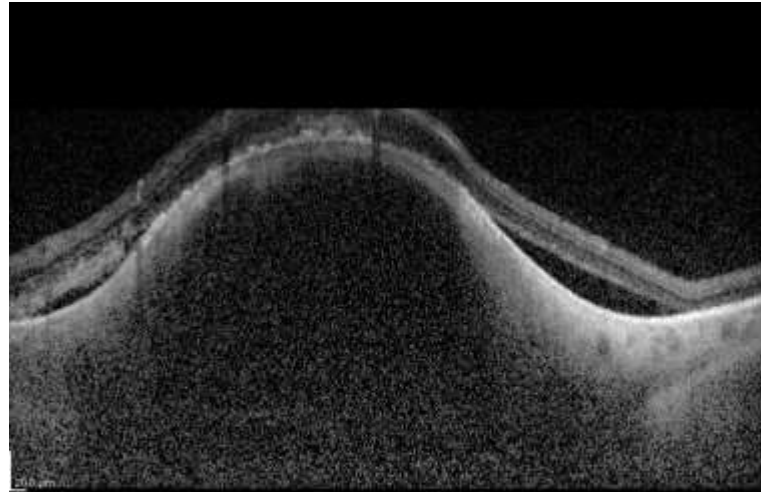
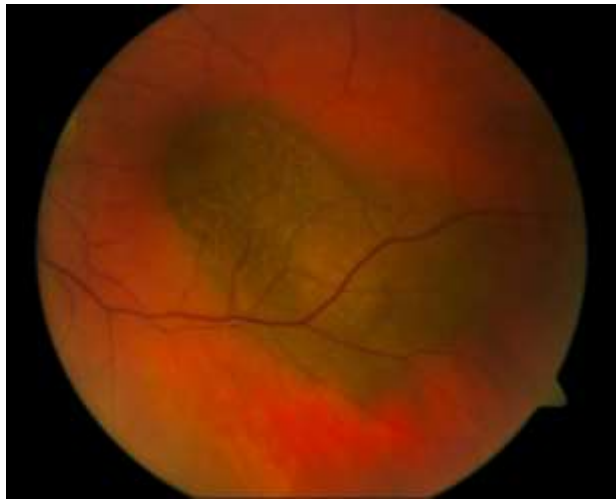- Most common primary sites
 - Women: breast
 - Men: lung
- "Lumpy bumpy" pattern



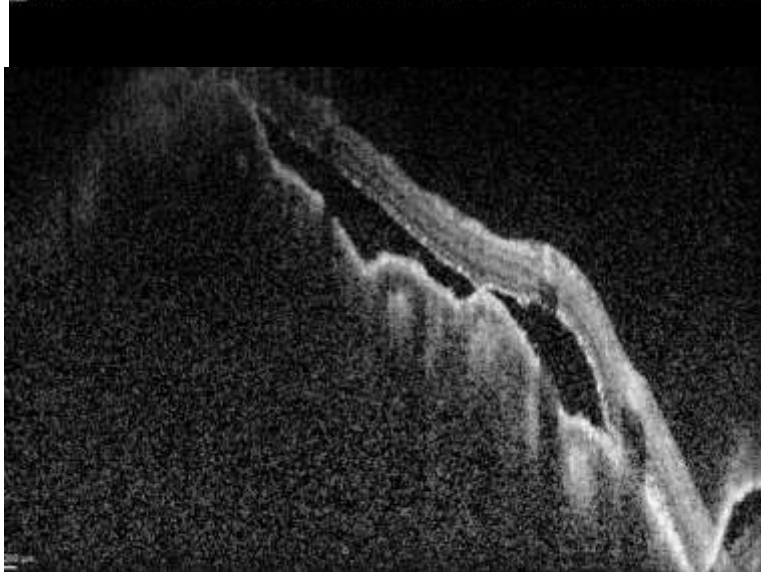
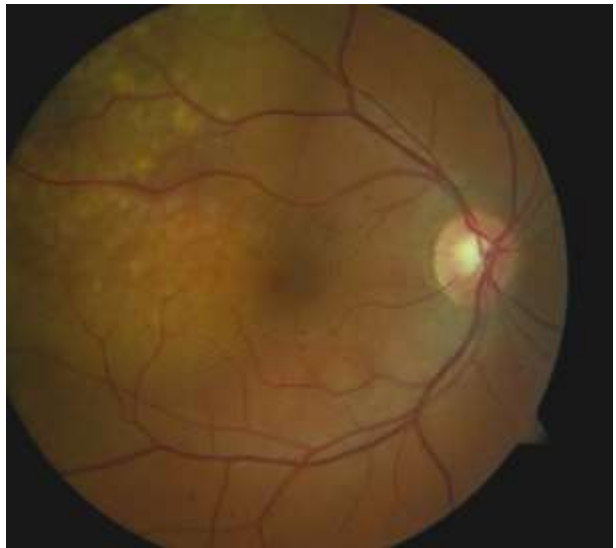RESPONSE TO TARGETED THERAPY



OCT MORPHOLOGY: AIDS IN DIAGNOSIS




Choroidal melanoma




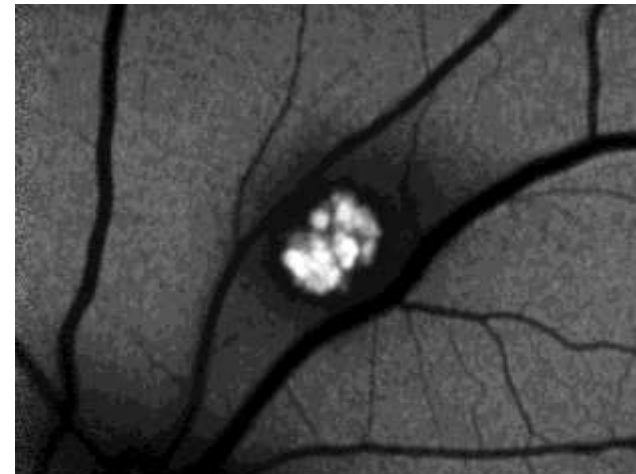
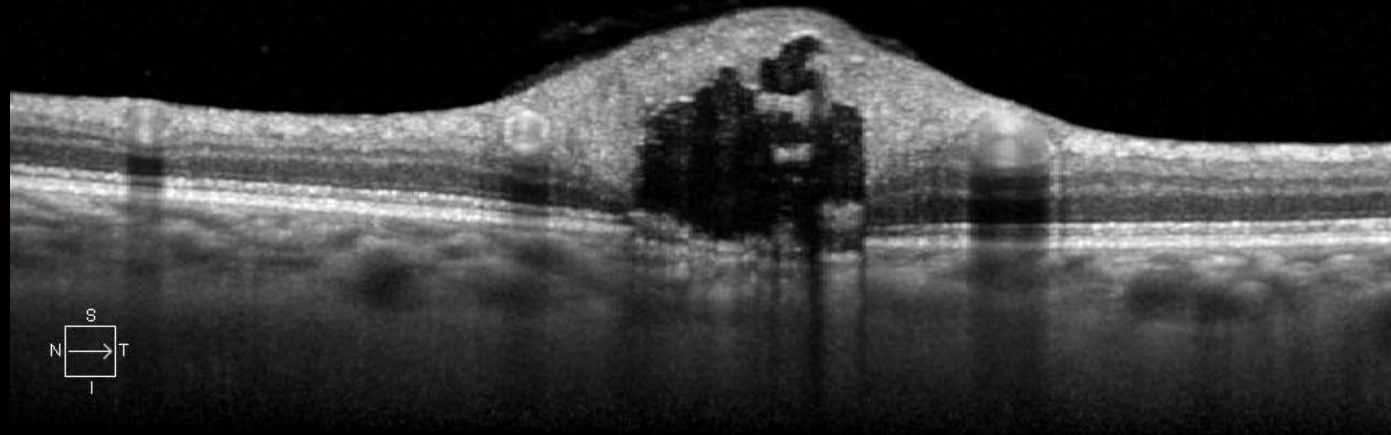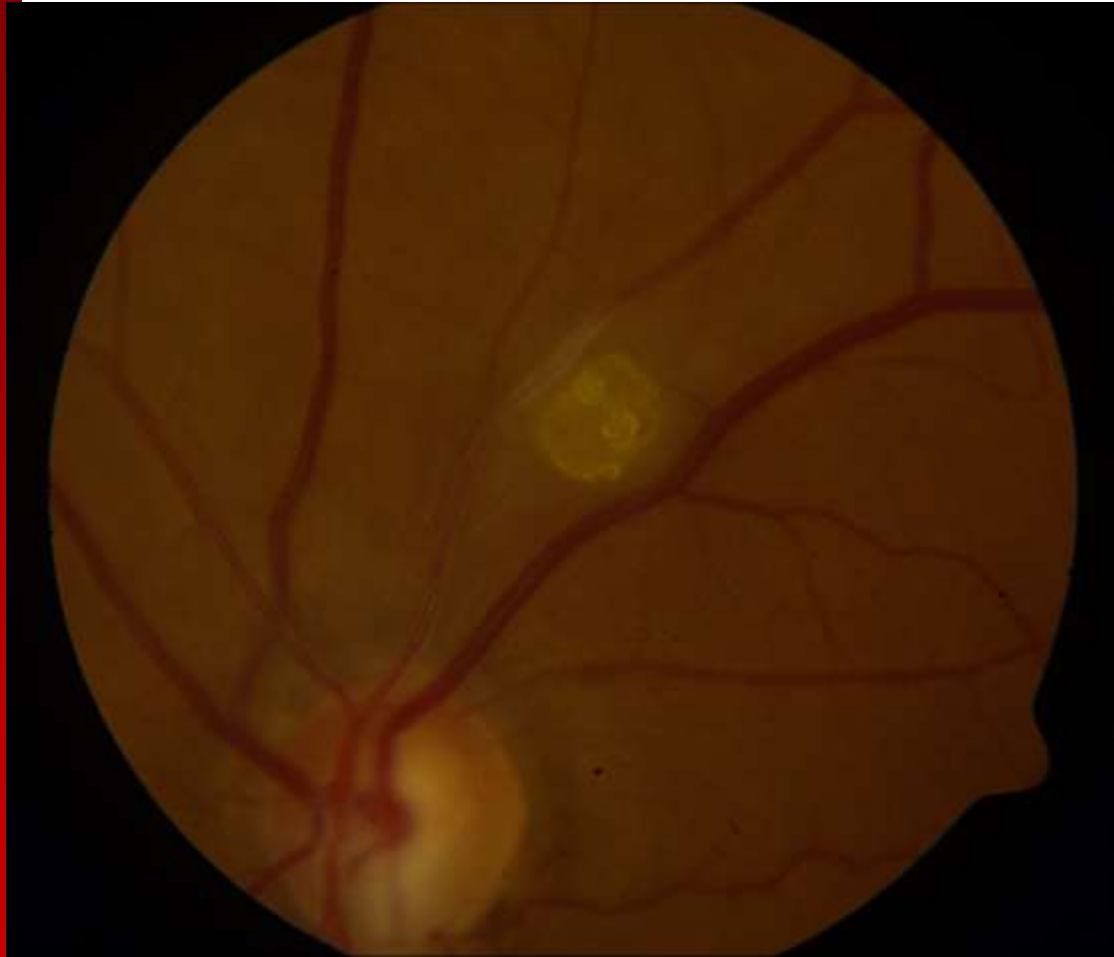
Choroidal metastasis



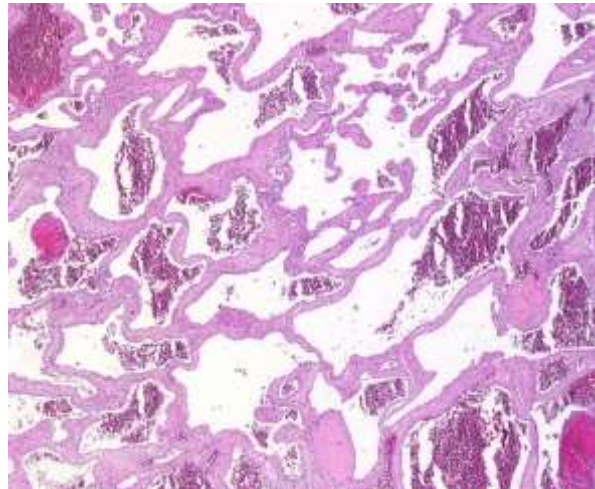
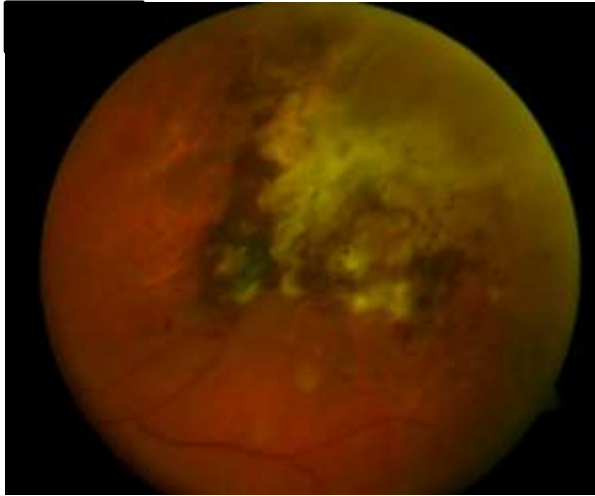
SOME TUMORS ARE IN/UNDER THE RETINA



ASTROCYTIC HAMARTOMA: “MOTH EATEN”



A TALE OF 2 HEMANGIOMAS...



Eagle et al. 1989

Cavernous

Sporadic

Rare

Unilateral

Neurocutaneous

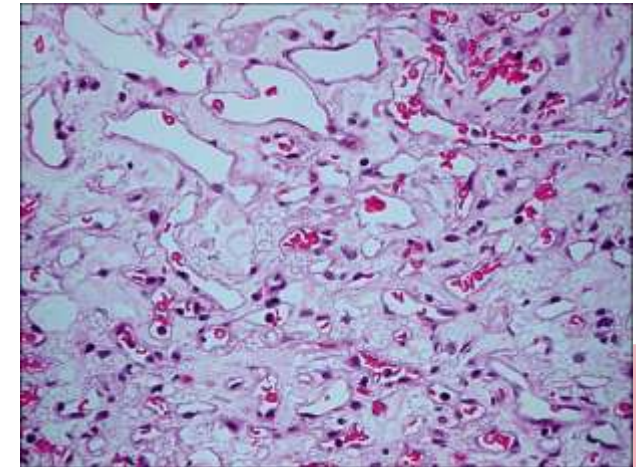
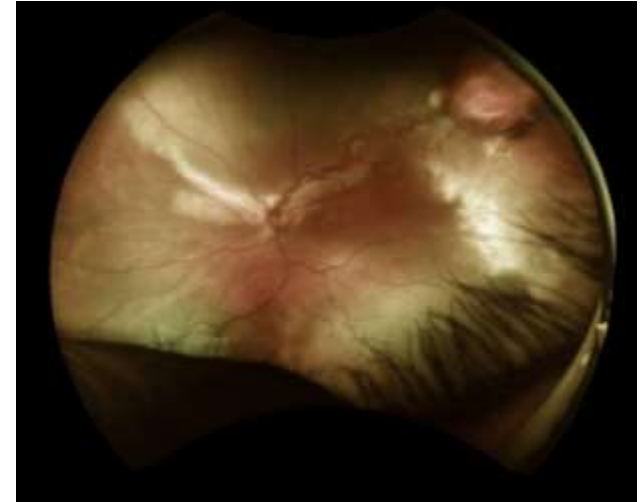
Capillary

Genetic

Common

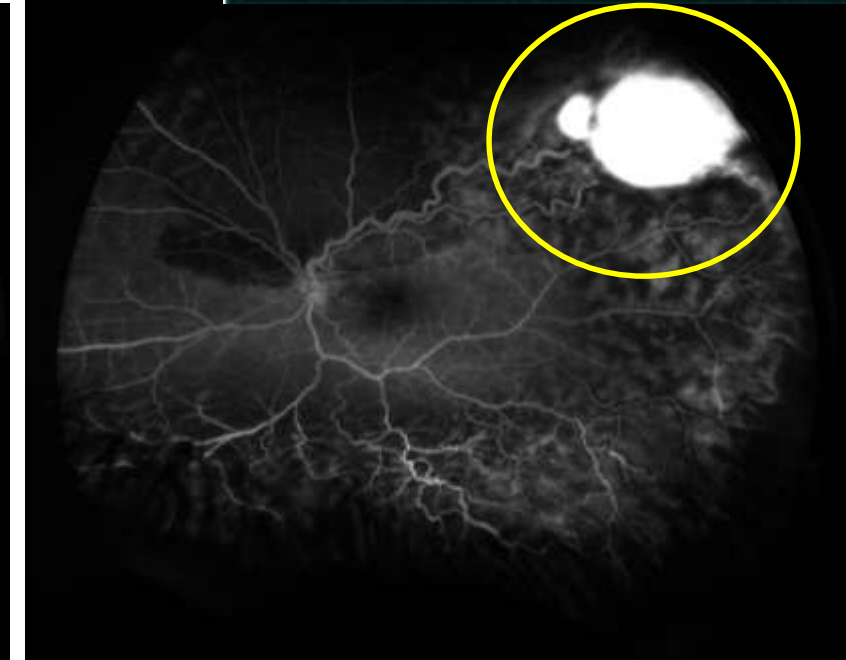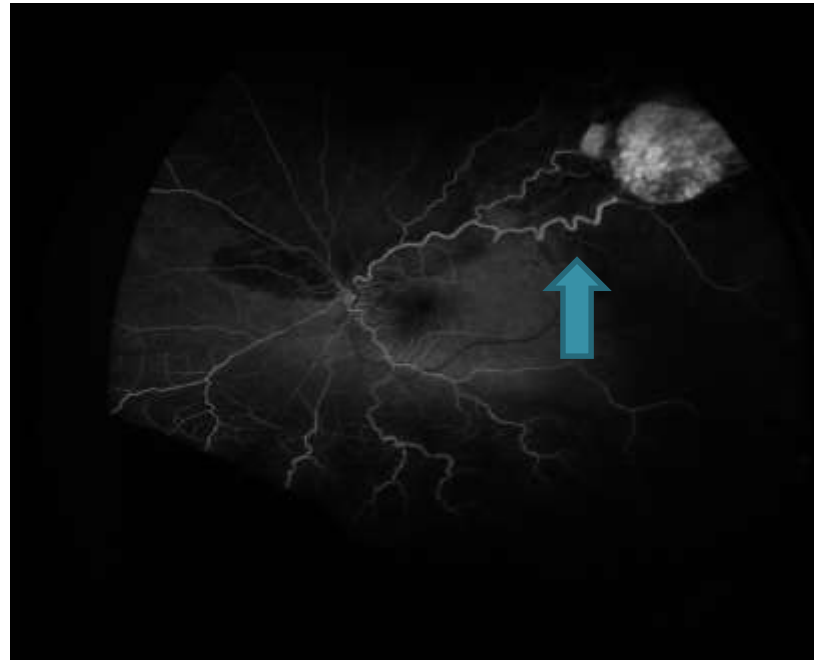
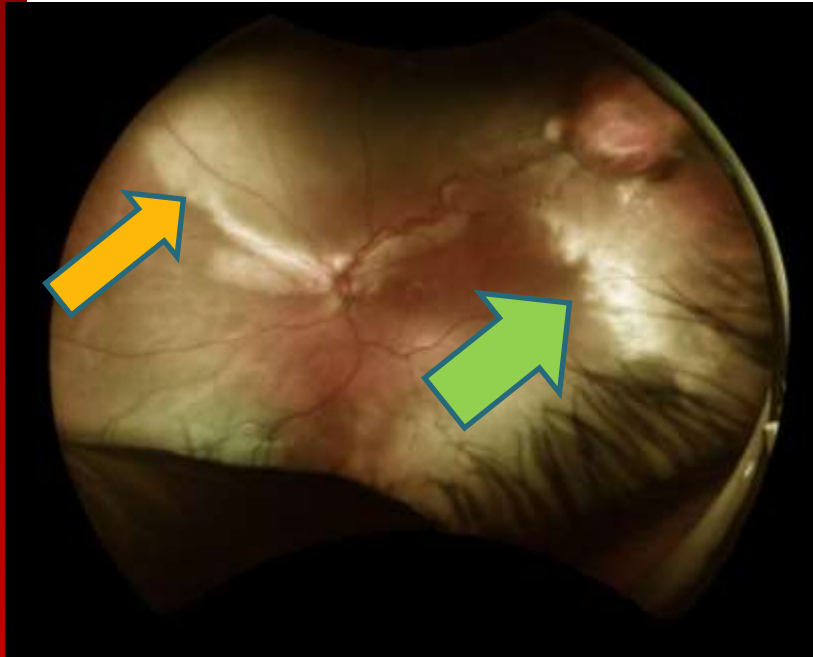
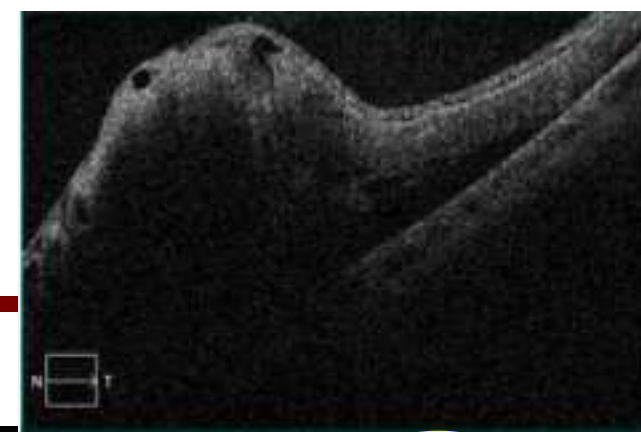Bilateral

Von Hippel Lindau



Schlesenger et al. 2007

CAPILLARY HEMANGIOMAS

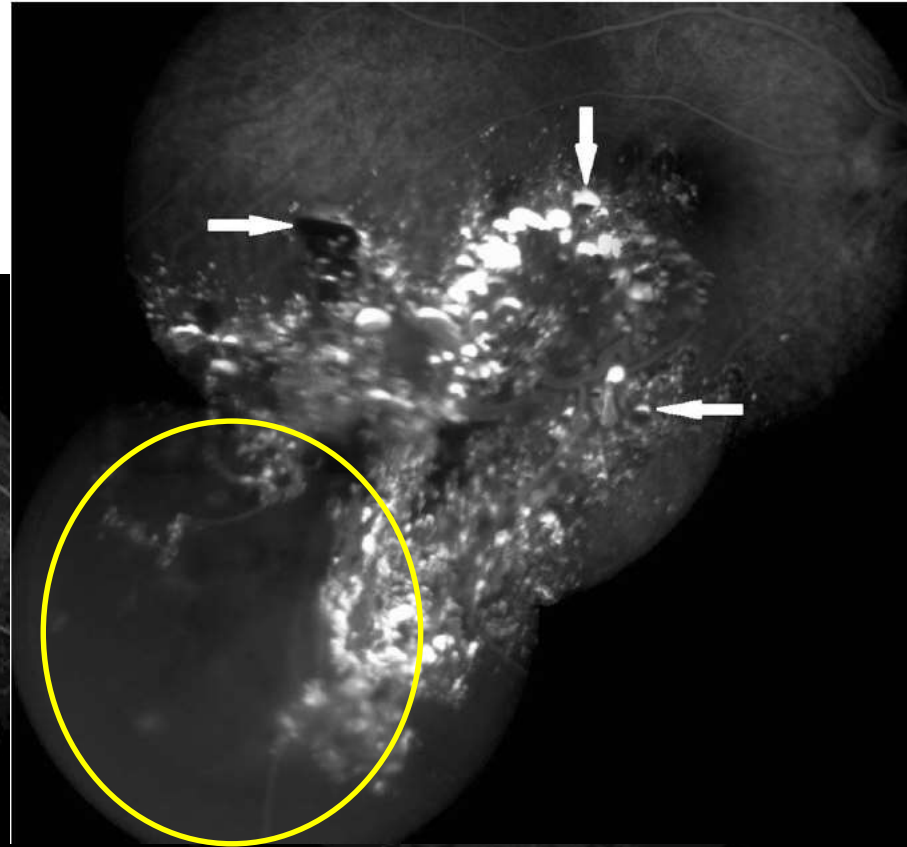
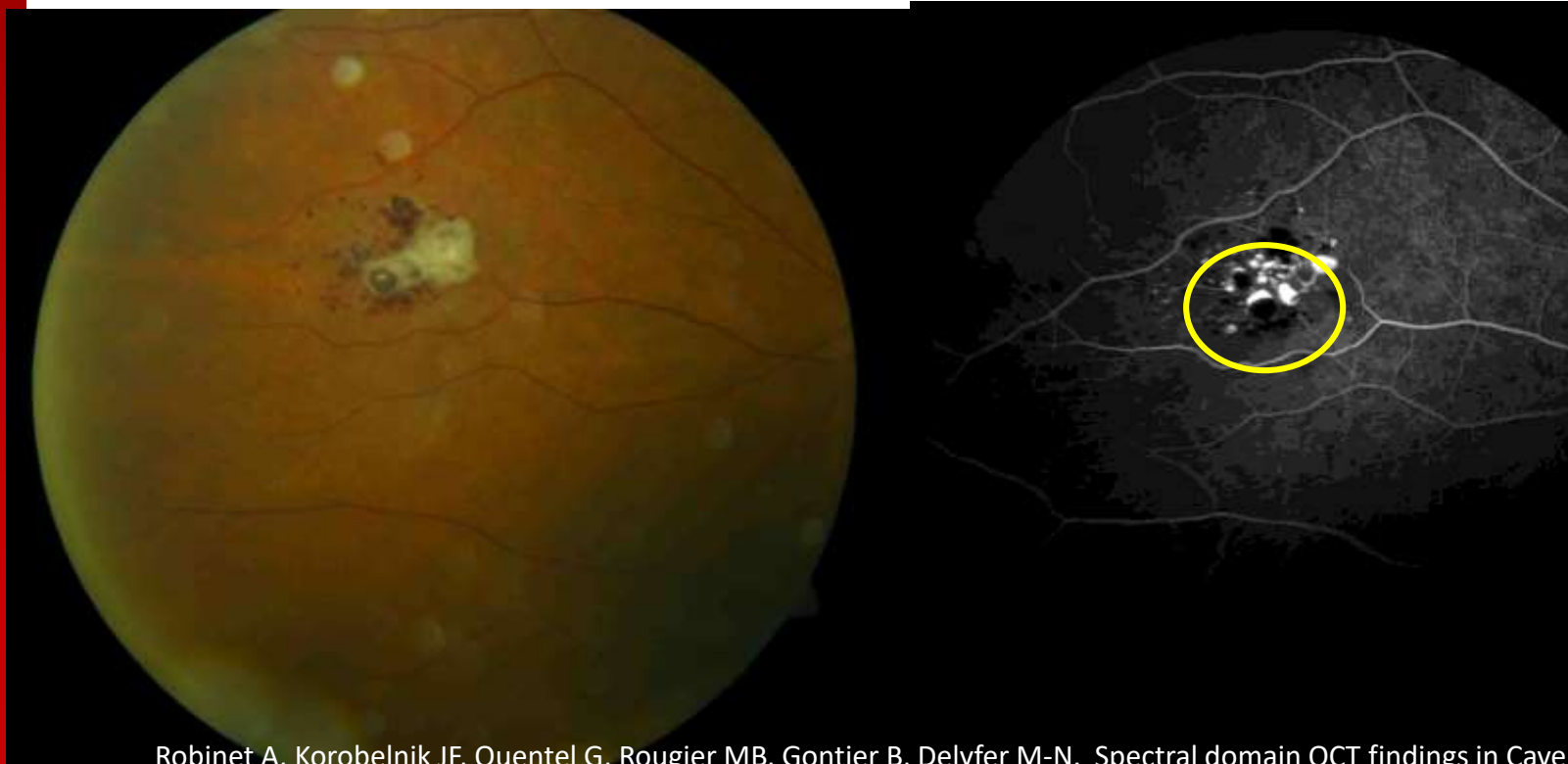
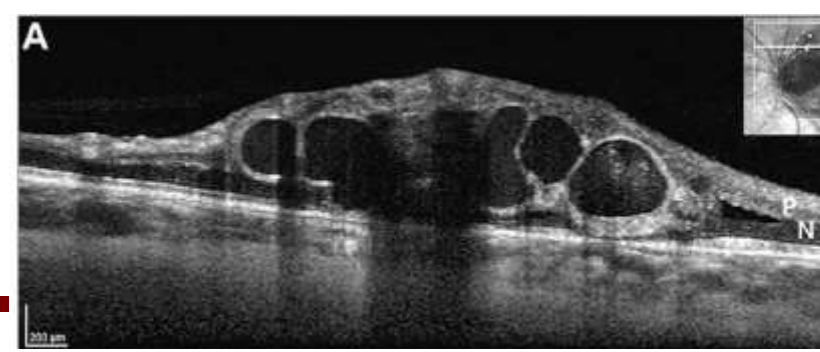


- Exophytic lesions :
 - efferent/afferent vasculature, early fill, late leak
 - exudation, subretinal fluid

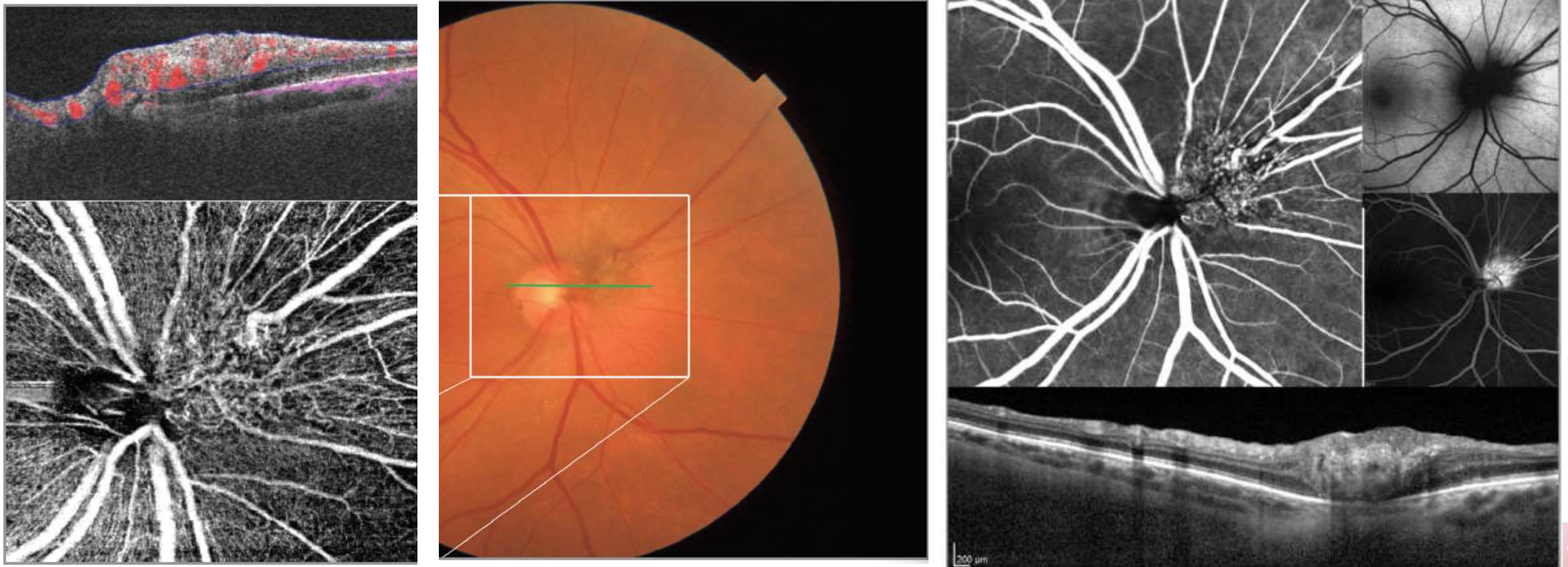


CAVERNOUS: "CLUSTER OF GRAPES"

- Normal retinal vasculature
- Fluorescein "cap"
- Retinal non perfusion



OCT-A AND CAVERNOUS HEMANGIOMA



Pierro L, Marchese A, Gagliardi M, Bandello F. Optical coherence tomography angiography of retinal cavernous hemangioma. *Ophthalmic Surg Lasers Imaging Retina*. 2017;48:684-685.]

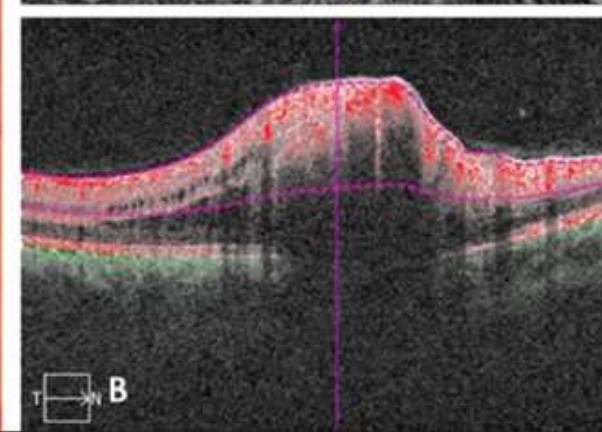
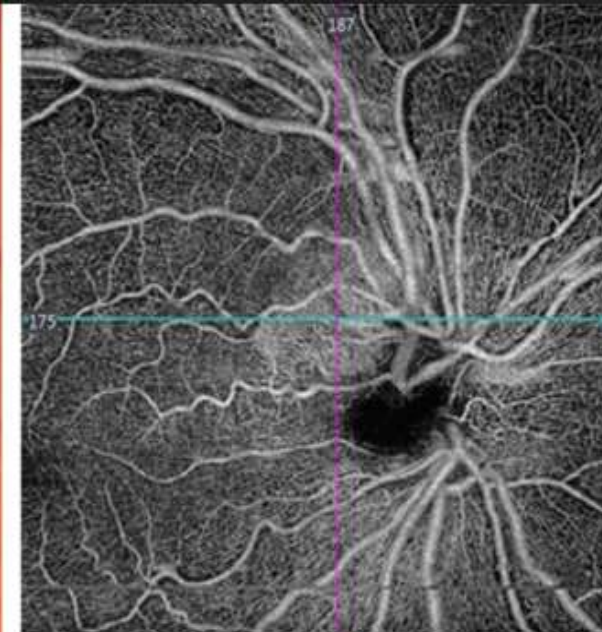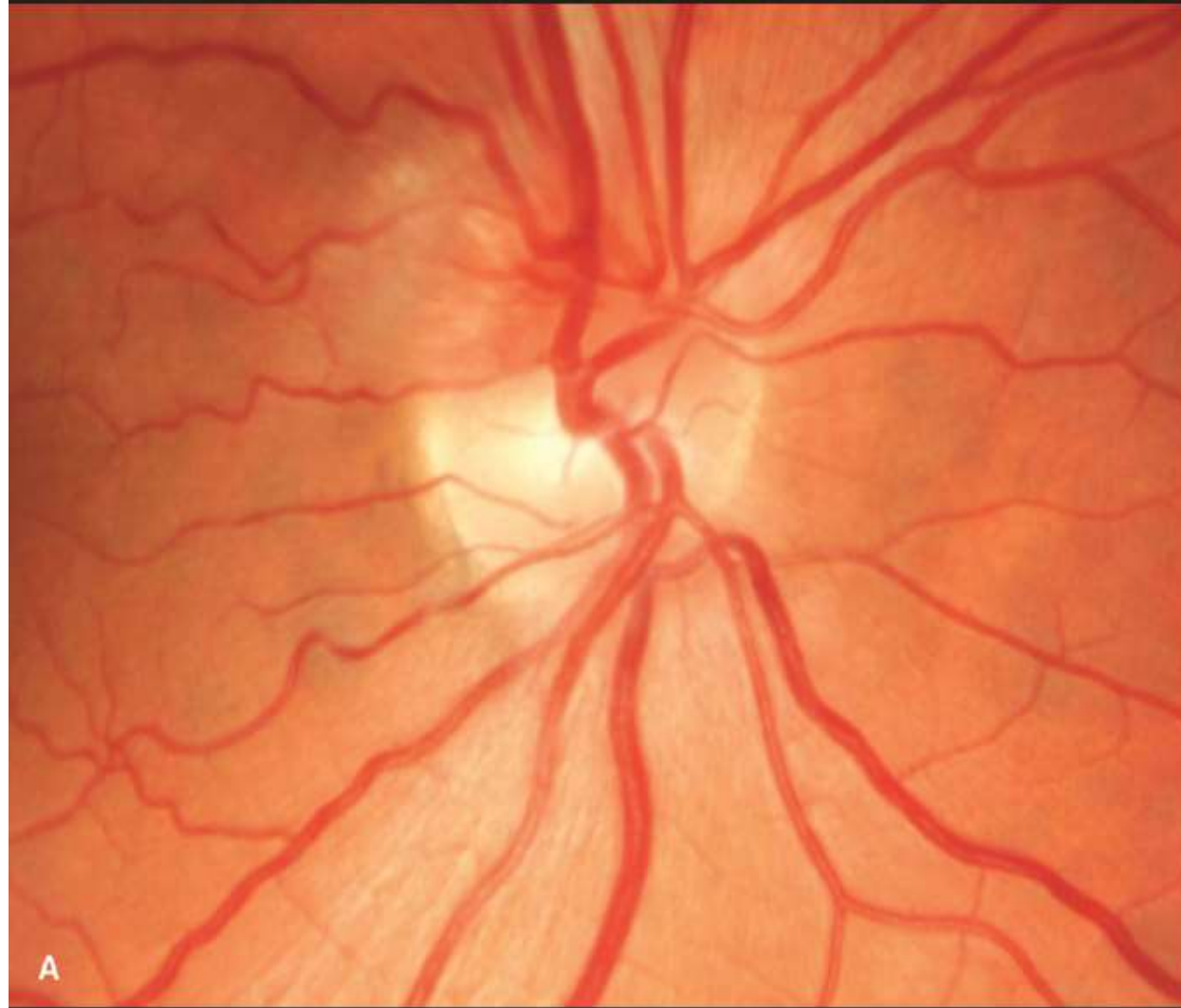

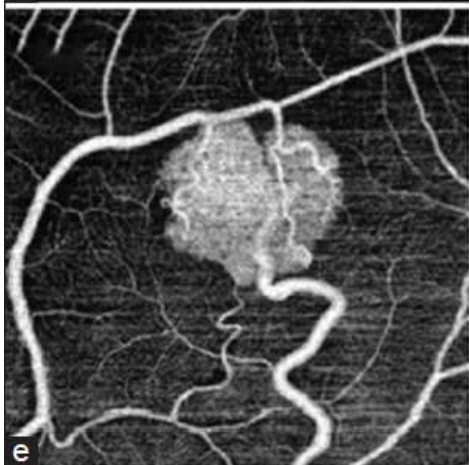
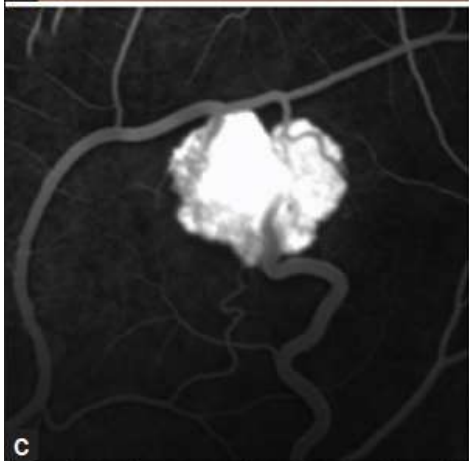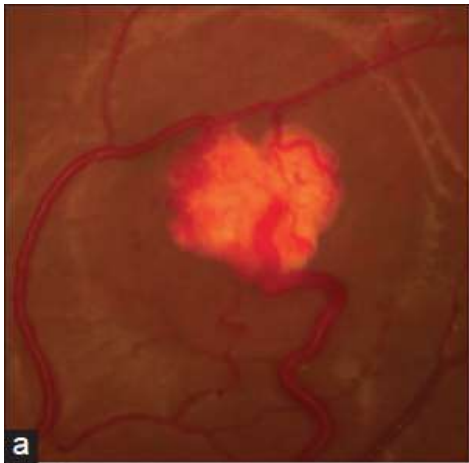OCT A

Value of Optical Coherence Tomography Angiography Imaging in Diagnosis and Treatment of Hemangioblastomas in von Hippel-Lindau Disease


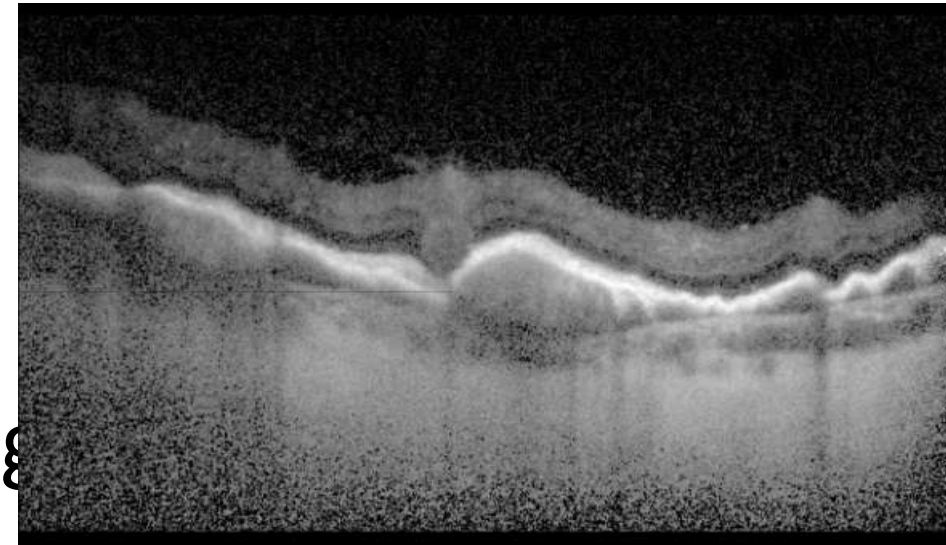
[*Ophthalmic Surg Lasers Imaging Retina*. 2016;47:935-946.]

Stefan J. Lang, MD; Bertan Cakir, MD; Charlotte Evers, MD; Franziska Ludwig, MD;
Clemens A.K. Lange, MD, PhD; Hansjürgen T. Agostini, MD


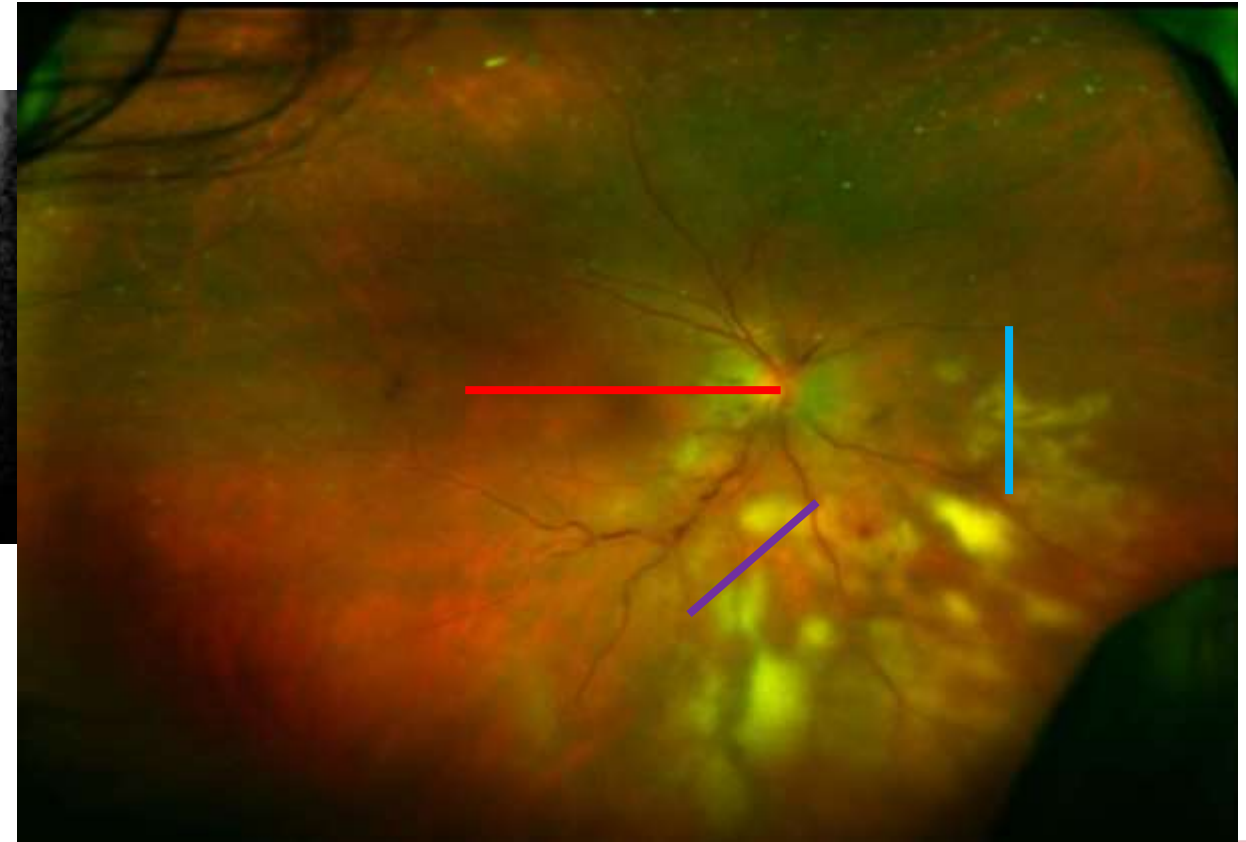
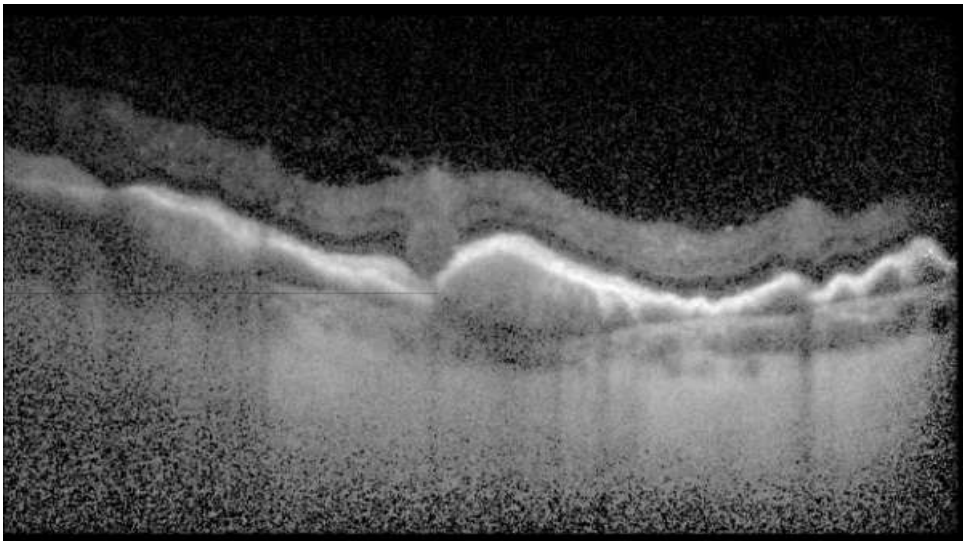
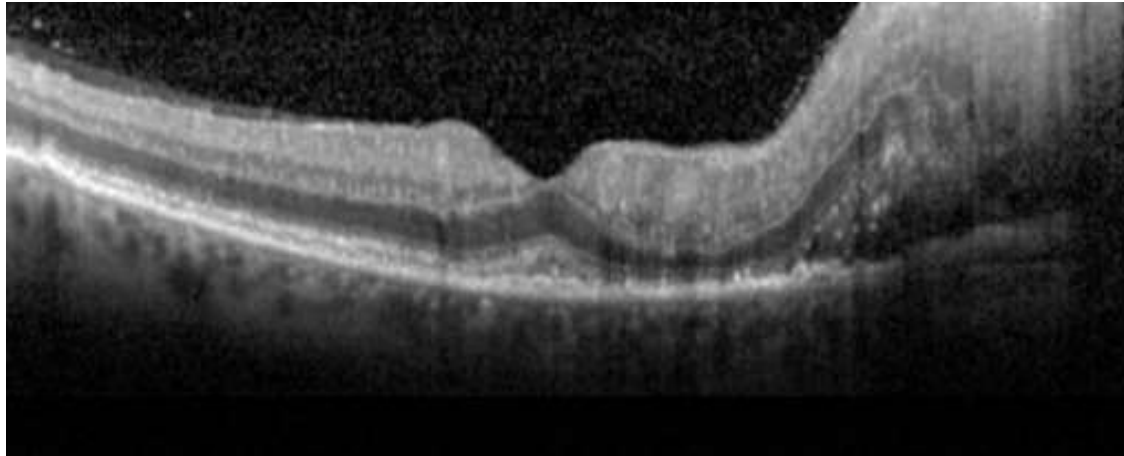
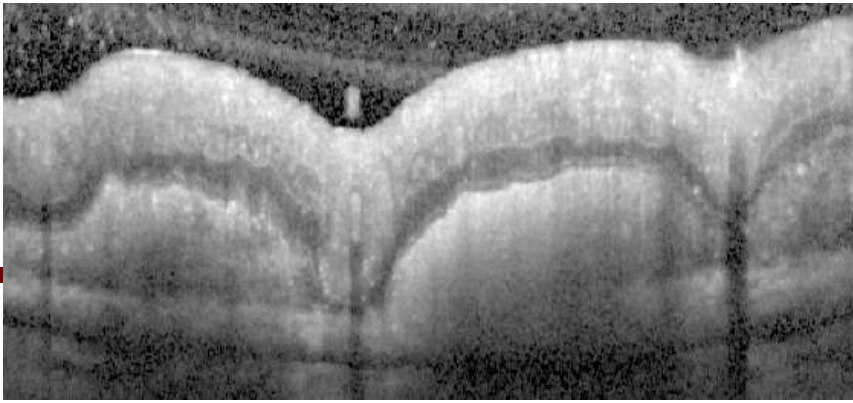


OCT AND INTRAOCULAR LYMPHOMA

- Visualize vitreous, retina, and choroid
 - All sites of lymphoma infiltration
- Secondary retinal effects
- Guidance for biopsy planning
- Eye tracking for serial monitoring
- Response to treatment

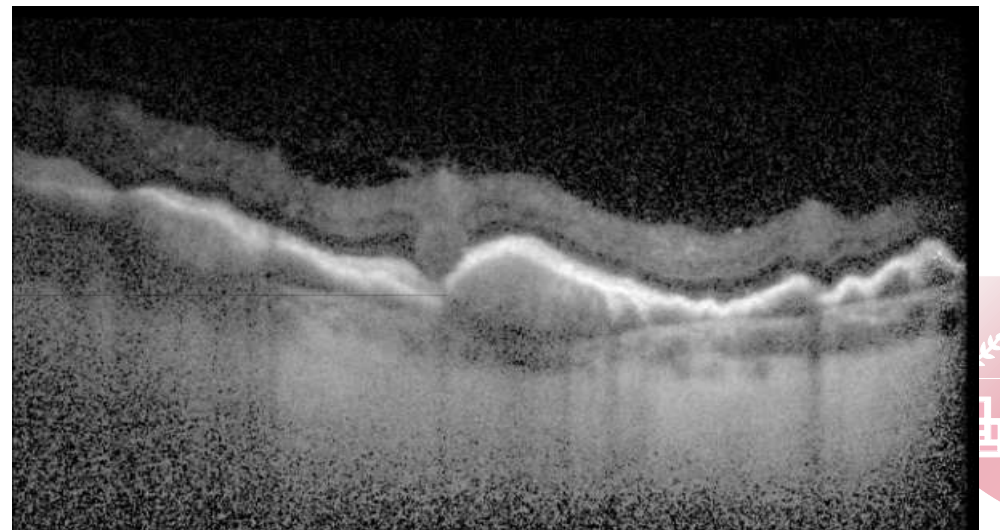
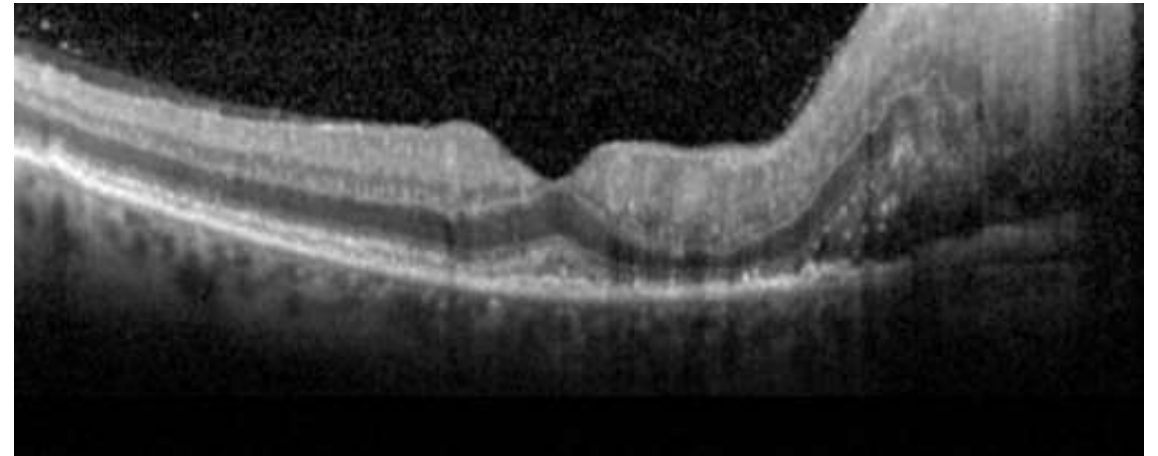
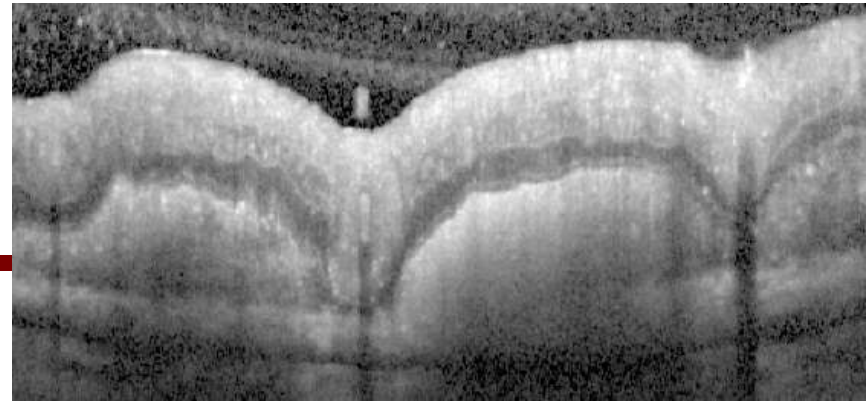

60 YOF WITH BLURRY VISION AND GAIT INSTABILITY



OCT FEATURES

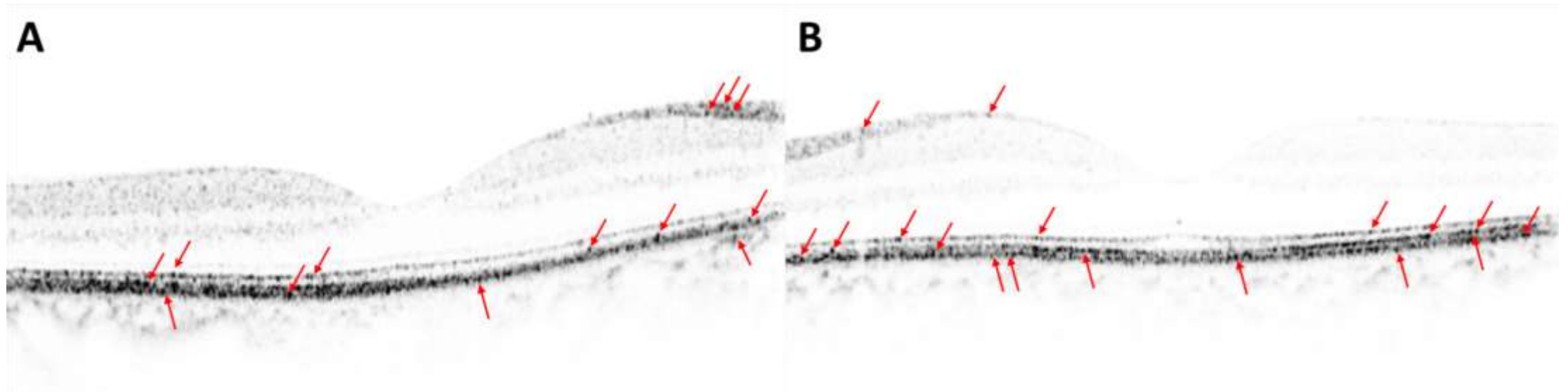
- Hyperreflective foci
 - Sub retinal 22%
 - Inner retinal 19%
 - Vitreous 16%
- Sub RPE deposits 9%
- RPE undulation 16%
- Vitreous HR 16%
- CME 8 %
- **VERY THIN epiretinal membranes (rare)**



Characteristic optical coherence tomography findings in patients with primary vitreoretinal lymphoma: a novel aid to early diagnosis




HYPERREFLECTIVE MICRO DEPOSITS



PCNSL with Intraocular Lymphoma

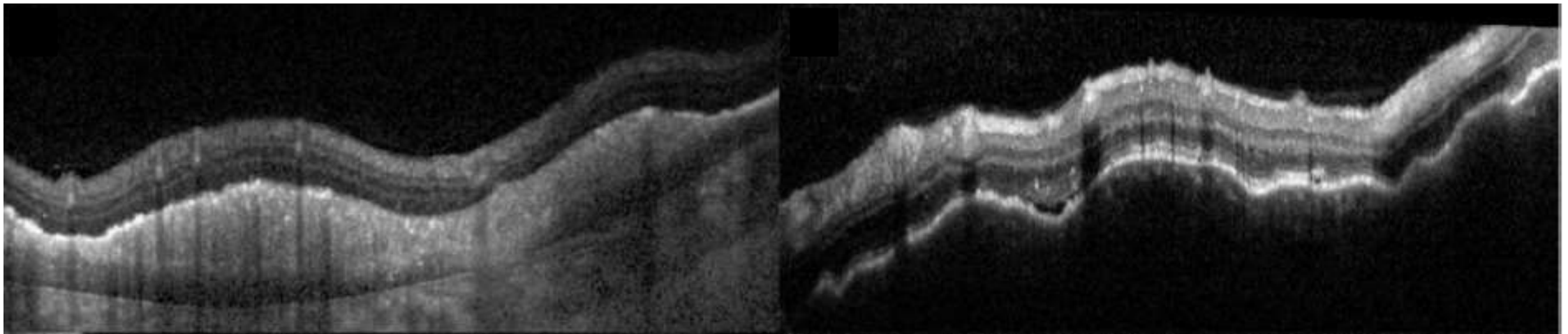
PCNSL without Intraocular Lymphoma

MUHAMMAD HASSAN, MD, MUHAMMAD SOHAIL HALIM, MD, ARASH MALIKI, MD, ANH
TRAN, BS, RUBBIA AFRIDI, MBBS, NAM NGUYEN, BS, YASIR J SEPAH, MD




CHOROIDAL LYMPHOMA

- Undulating RPE
- No separation between RPE and Bruch's
- Choroidal thickening

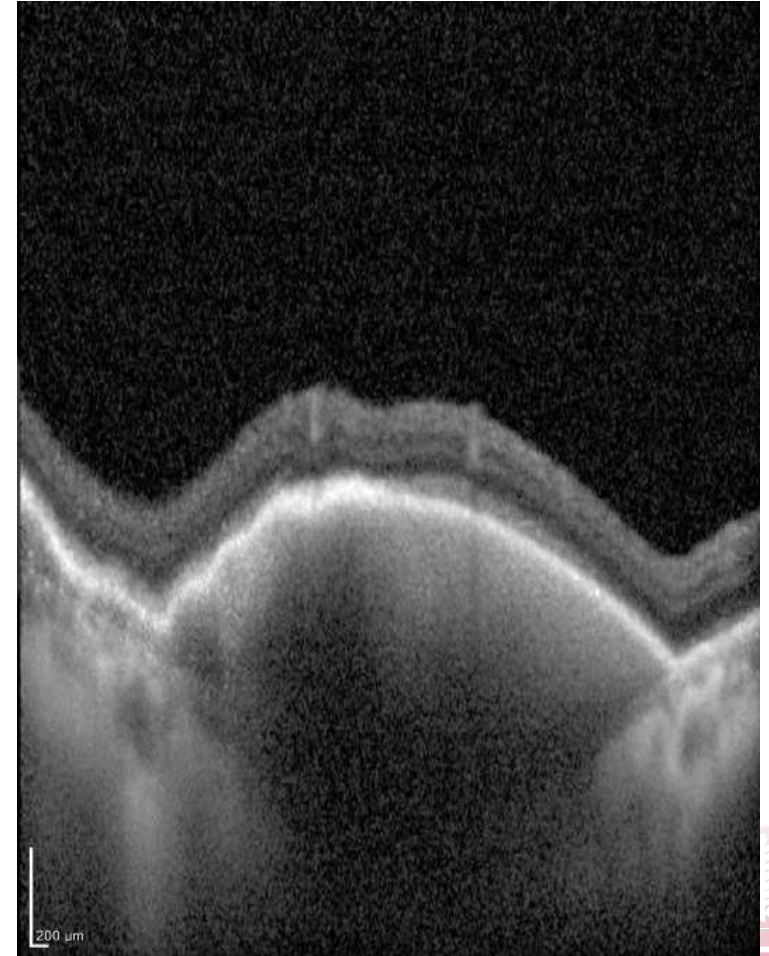
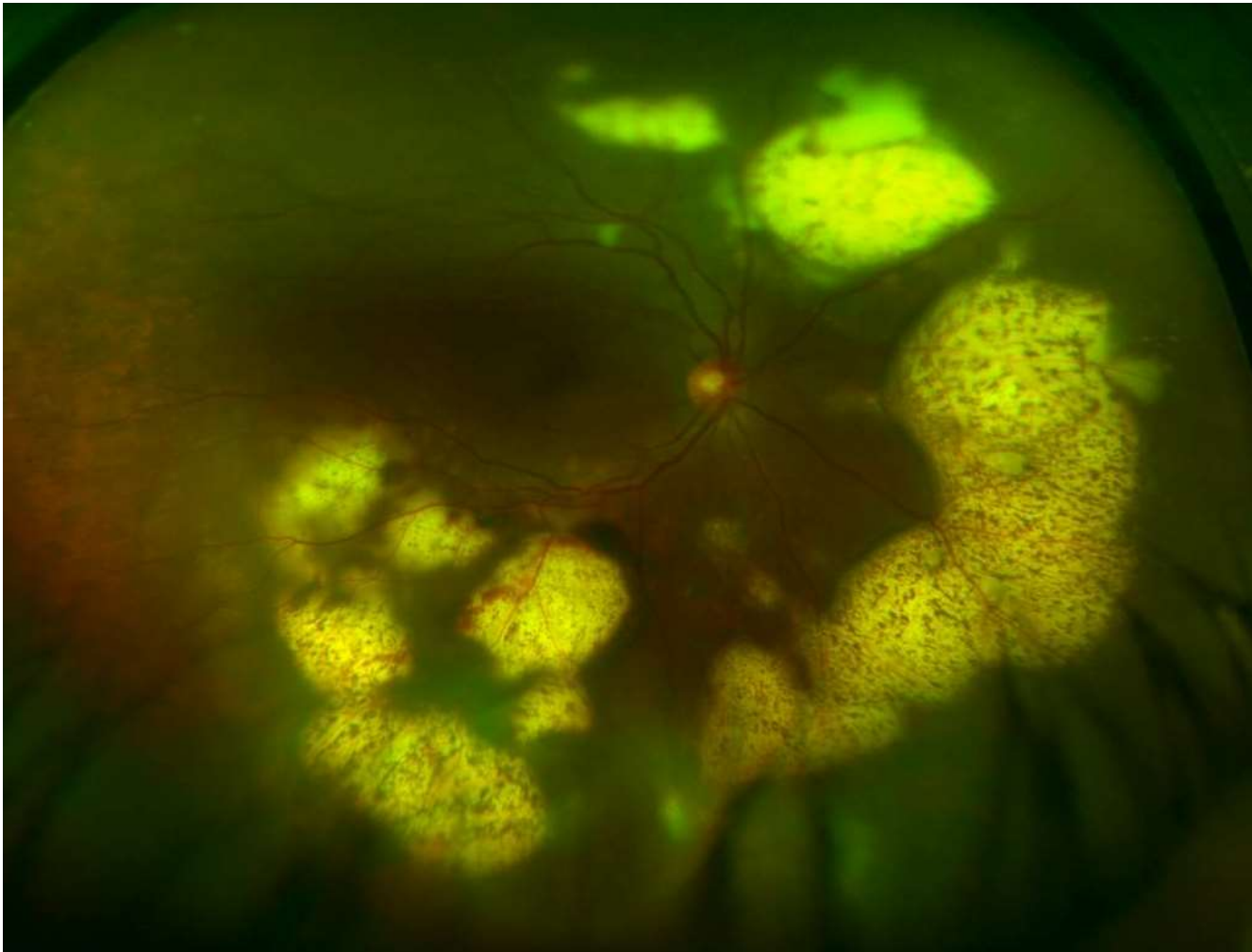


Vitreoretinal lymphoma


Choroidal lymphoma




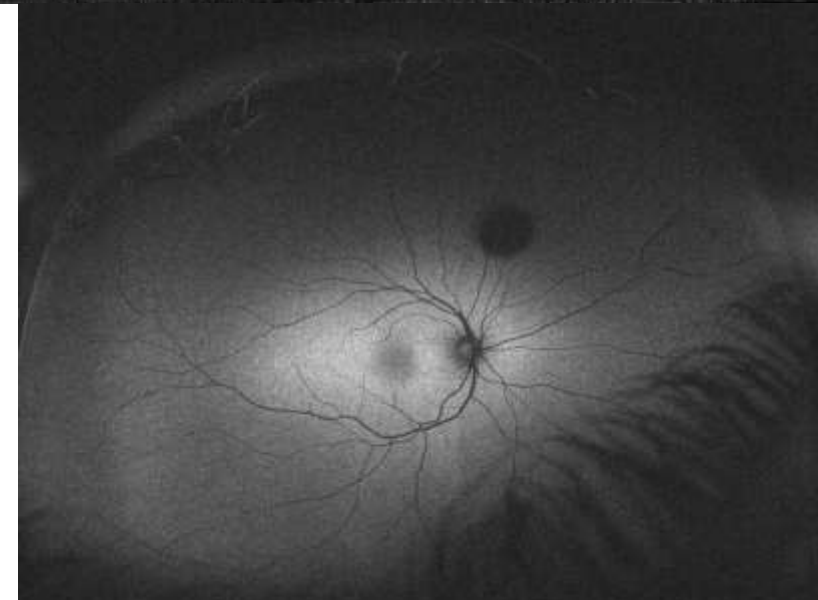
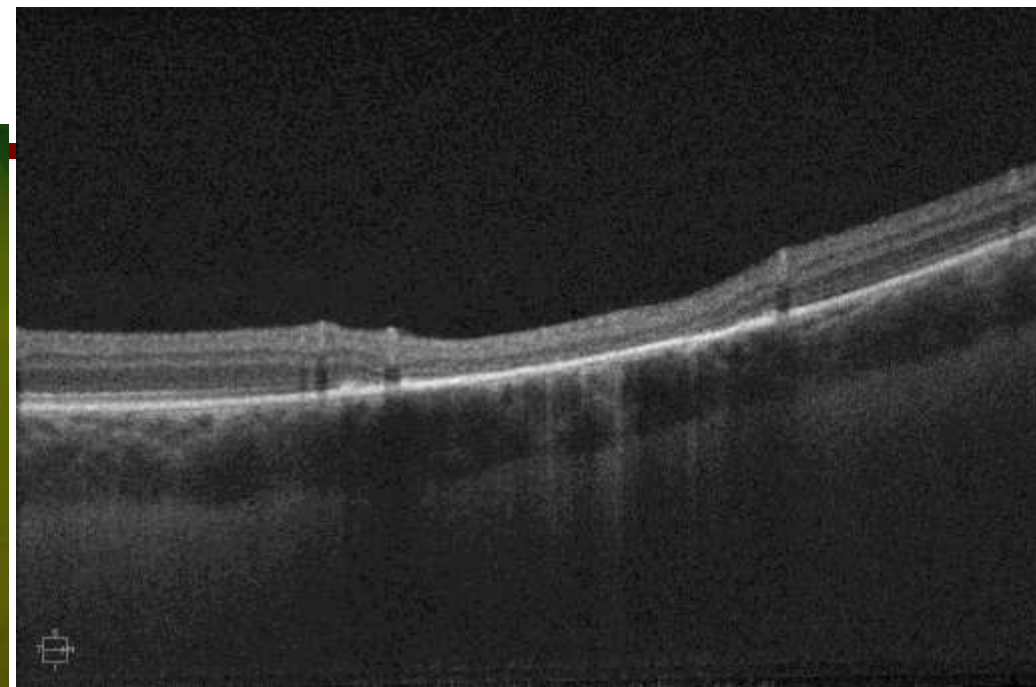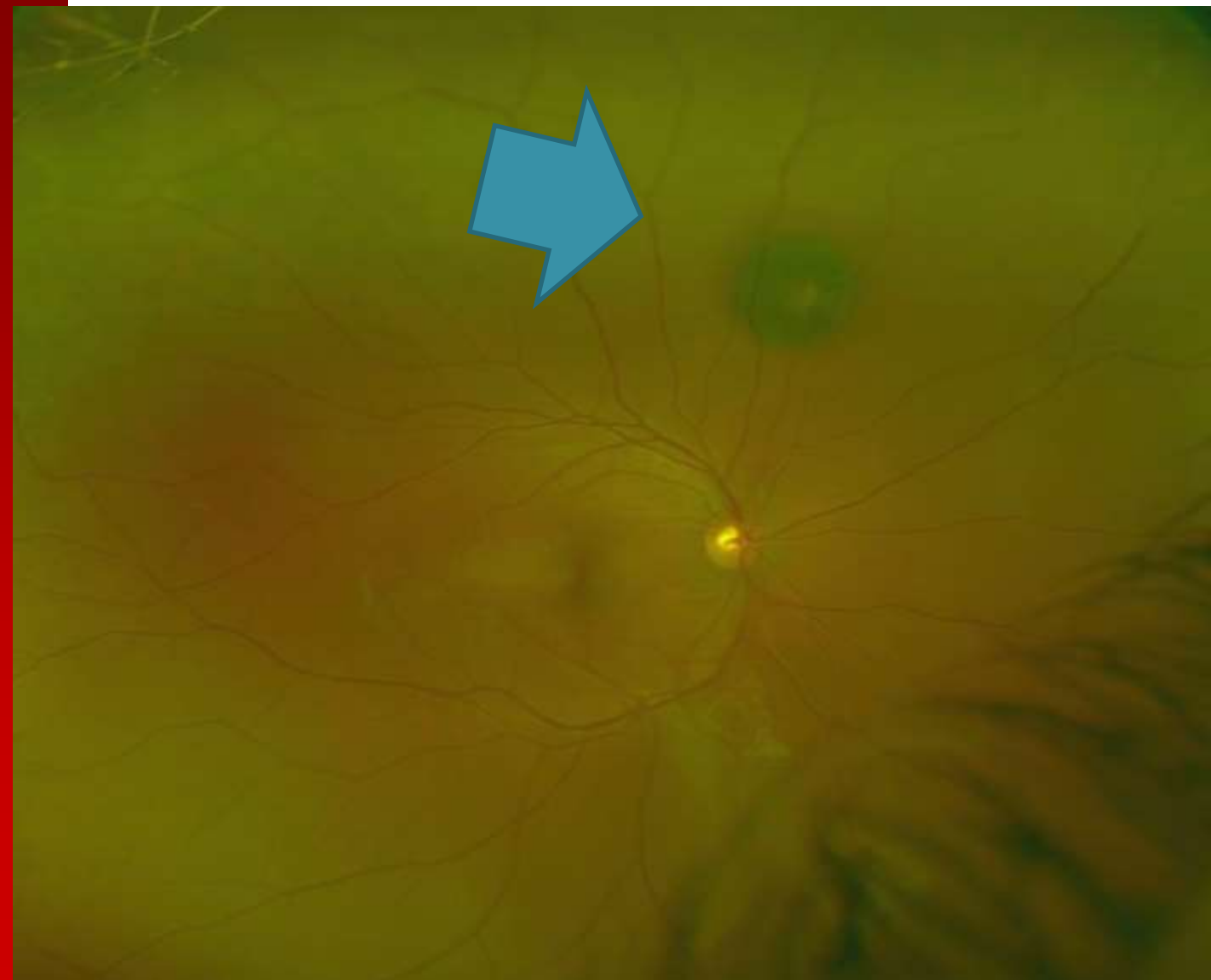
SECONDARY UVEAL LYMPHOMA : METASTATIC



SOME TUMORS IN THE RPE




CHRPE



POSTERIOR TUMOR OCT: TIPS

- Thickness: flat vs. thick lesions
- Look for surface features (fluid, drusen)
- Identify which layer the tumor is located

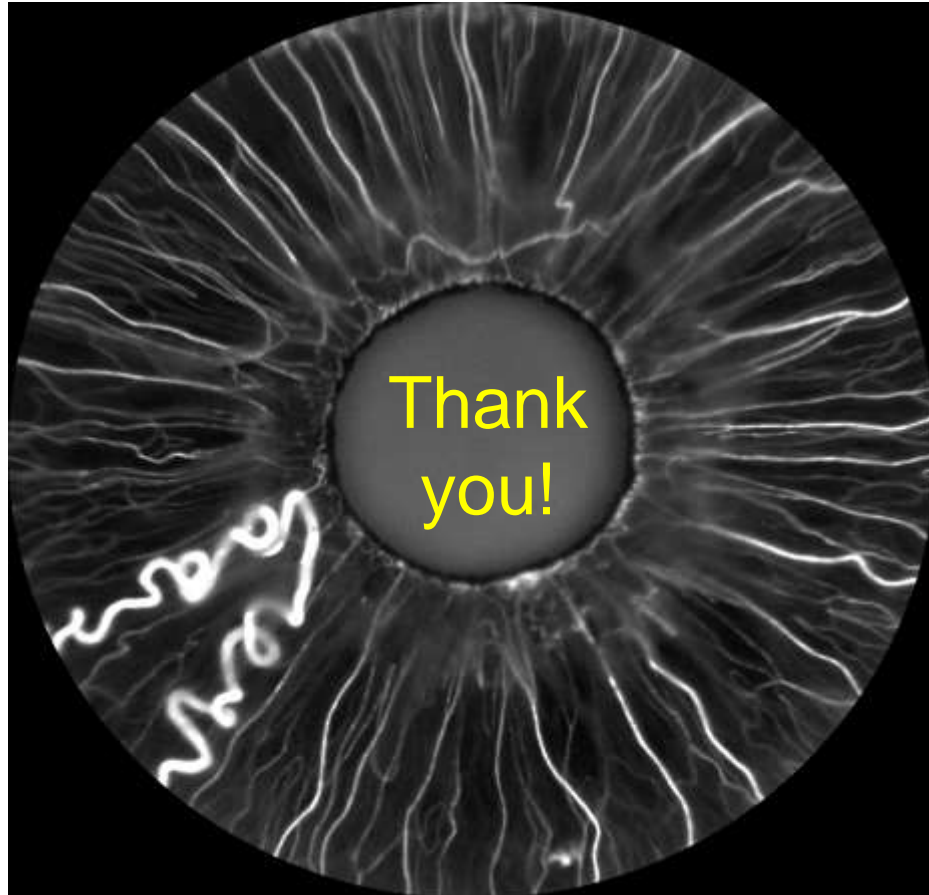- Morphology distinguishes tumor



STANFORD OCULAR ONCOLOGY SERVICE



Stanford
OPHTHALMOLOGY
BYERS EYE INSTITUTE



Orbital
Eyelid
Tumors

Ocular
surface
Tumors

Pediatric
Tumors
Retinoblastoma

Intraocular
Tumors
Melanoma

Systemic
cancers and
the eye

Prithvi Mruthyunjaya, MD, MHS *Director*

Andrea Kossler, MD *Director, Orbital Oncology*

Ben Erickson, MD

Albert Wu, MD

ocularoncology@stanford.edu

