Methotrexate Neurotoxicity: An Uncommon Cause of Encephalopathy and Stroke-Like Symptoms in the Pediatric Population

Melissa Tsuboyama, MD

University of Rochester Medical Center, Rochester, NY

CASE REPORT

- 13 year old right handed girl with recently diagnosed non-metastatic osteosarcoma of the right femur admitted for high dose methotrexate with leucovorin rescue
- Day 1: received high dose methotrexate- no intrathecal administration
- Day 2: Fever to 39.9 and started on ceftriaxone, delayed methotrexate clearance so fluid rate increased
- Day 3:
  - Persistently febrile, switched to cefepime
  - RRT for fever, tachycardia, tachypnea → diagnosed with non-occlusive pulmonary embolism and started on therapeutic lovenox
  - Lower extremity ultrasound showed no DVTs
  - Evening: unstable when walking, "didn't know what was going on"
- Day 4:
  - Making strange noises "eee", appeared confused and not understanding what was going on around her
  - Head CT in the morning unremarkable
  - Evening- favoring left hand: grabbing onto rail with left hand, giving high five only with left hand; making strange facial expressions (grimacing, smiling); couldn't recall who various family members in the room were
  - Developed tachypnea, high fever, hypertension with SBP 135, and hypoxia requiring nasal cannula and then non-rebreather
- Had delayed methotrexate clearance
- Exam on evening of Day 4: rarely following commands, exam limited by poor cooperation, unable to name objects or state name or location, no cranial nerve abnormalities, no focal weakness

NEUROIMAGING (DWI)

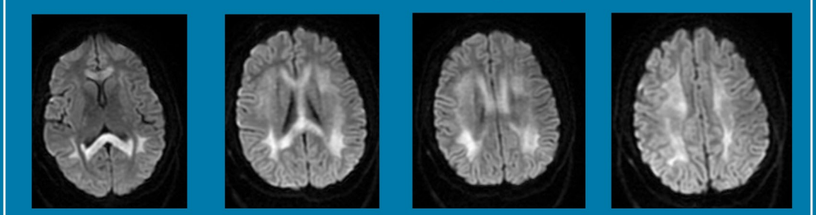

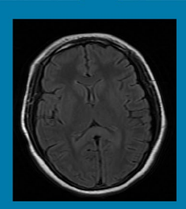

Symmetric regions of restricted diffusion involving the centrum semiovale, deep white matter, and corpus callosum, with minimal associated T2/FLAIR

Methotrexate Neurotoxicity and Leukoencephalopathy

- Incidence (in patients with ALL) 9%-53%
- Signs/symptoms:
  - Headache
  - Seizures
  - Aphasia
  - Hemiparesis
- Risk factors:
  - High-dose treatment
  - Intrathecal treatment
  - Young age
  - Association with cranial radiation
  - NO relation to 42 hour MTX level as it relates to leucovorin dose
- Onset: 2-14 days after intrathecal, high-dose, or prolonged low-dose methotrexate
- Imaging:

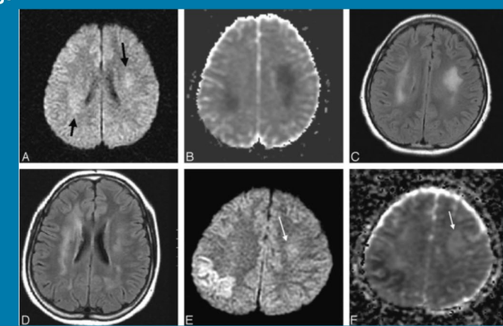

Rollins N, 2004

T2 hyperintensities in the periventricular white matter, particularly in the centrum semiovale

PROPOSED PATHOGENESIS

- 1) Increased adenosine accumulation
- 2) Elevated homocysteine → excitatory effect on NMDA receptor
- 3) Alterations of biopterin metabolism
- 4) Direct neurotoxic effect of methotrexate on cell

- Germline polymorphisms can contribute to methotrexate-induced leukoencephalopathy and neurotoxicity: GSTP1, MTHFR, SHMT1

TREATMENT & OUTCOMES

- No standard therapy other than supportive care
- Dextromethorphan (DM), NMDA antagonist
  - In study of 18 patients with sudden onset of neurological impairments after receiving methotrexate
    - Typical dose 1 mg/kg BID for 1-7 days
    - Group A: 8/18 patients received DM > 24 hr after symptom onset
    - Group B: 10/18 patients received DM < 24 hr from symptom onset

	Group A	Group B
Time to initial response after DM	13.9 hours	3.5 hours
Time to resolution of impairments	2 hours – 7 days (1 pt 1 month)	~2-7 days (1 pt- 20 days; 1 pt- 8 weeks)

- Amophylline (adenosine antagonist)
- Majority of patients have resolution of symptoms, most reports are within 1 week
- Diffusion abnormality on MRI also resolves with interval development of abnormal FLAIR

CASE OUTCOME

- Patient admitted to the PICU
- Found to have strep pneumoniae pneumonia, placed back on ceftriaxone
- Around the clock Tylenol and Ibuprofen helped minimize hyperthermia which also helped mental status
- Over the course of ~48 hours returned to baseline without residual deficits
  - Improvement evident within 12 hours of symptom onset so DM not administered
- Eventually finished clearing methotrexate and was discharged home
- Undergoing resection of osteosarcoma in 1-2 weeks

QUESTIONS

- Will she be re-challenged with high dose methotrexate as part of her chemotherapy regimen in the future should it be indicated?
  - No clear contraindications

REFERENCES

(1) Afshar M, et al. Review of Dextromethorphan Administration in 18 Patients With Subacute Methotrexate Central Nervous System Toxicity. *Pediatr Neurol* 2014; 50: 625-629.
(2) Badke C, et al. Rechallenging With Intrathecal Methotrexate After Developing Subacute Neurotoxicity in Children with Hematologic Malignancies. *Pediatr Blood Cancer* 2016; 63: 723-726.
(3) Fisher MJ, et al. Diffusion-Weighted MR Imaging of Early methotrexate-Related Neurotoxicity in Children. *AJNR Am J* Neuroradiol 2005; 26: 1686-1689.
(4) Bhojwani D, et al. Methotrexate-Induced Neurotoxicity and Leukoencephalopathy in Childhood Acute Lymphoblastic Leukemia. *J Clin Oncol* 2014; 32: 949-959.
(5) Muller J, et al. Toxic Encephalopathy and Delayed MTX clearance after High-Dose Methotrexate Therapy in a Child Homozygous for the MTHFE C677T Polymorphism 2008; 28: 3051-3054.
(6) Rollins N, et al. Acute Methotrexate Neurotoxicity: Findings on Diffusion Weighted Imaging and Correlation with Clinical Outcome. *AJNR Am J Neuroradiol 2004*; 25:1688-1695.