Unilateral Papilledema: A Case of Neurosyphilis

Jennifer Marsella, MD
UR Medicine, Rochester, NY

Introduction

The incidence of syphilis, the "great imitator," has steadily increased since the beginning of the millennium, warranting a higher level of suspicion for patients with characteristic neurologic symptoms and signs suggestive of neurosyphilis.

Mr. CF is a 51 year old man who had two months of transient episodes of right-sided visual loss and headaches.

HPI

January: 10 pound weight loss
February: low-grade fevers and fatigue for several weeks
March: diagnosed with primary biliary cirrhosis, started on ursodiol
April: whiting out of vision in the right eye, occurring 3-15 times per day, duration of 10 seconds, no warning signs, no eye pain, headache, photophobia
May: non-pruritic rash on chest and arms, no improvement with Bactrim nor prednisone
June: seen by ophthalmology, found to have right optic disc edema
July/August: referred to neuro-ophthalmology, found to have diffuse disc edema, venous engorgement, and an enlarged blind spot on the right, but no evidence of optic nerve damage

Medical History

Medical History: Primary Biliary Cirrhosis, GERD
Surgical History: Right shoulder surgery (2010), Back surgery
Family History: Father: stroke, lung cancer, and diabetes
Mother: Alzheimer's
Sister: cancer
Social History: Married with 2 children, works in construction, current smoker, no EtOH use since PBC diagnosis, remote drug use
Medications: Ursodiol 300 mg TID, Famotidine 20 mg daily, Aspirin 81 mg daily, Ibuprofen prn, Oxycodone IR 5 mg prn
Allergies: None
ROS: positive for changes in vision, headache, and heartburn

Laboratory Data

ANA negative, ESR 17, CRP 4, ACE 20, Anca negative, Anti-RNP 0.7, Anti-Smith <0.2, Anti-SSA/SSB <0.2, Anti-dsDNA 3, SM/RNP AB <0.2, HIV negative, Lyme IgG/IgM negative, Serum RPR: reactive, titer 1:128; TPPA positive

CSF (early August):
Color: clear, colorless
Opening pressure 15
Nucleated cells 52-->30
RBC 102-->0
Lymphs 83-->86
Monos 17-->12
Glucose 55
Protein 117
Gram stain: 0 PMNs, no organisms
Aerobic culture: no growth

CSF (late August):
Color: clear, colorless
Opening pressure 14.5
Nucleated cells 61-->28
RBC 182-->2
Lymphs 89-->72
Glucose 47
Protein 109
Oligo bands negative
Flow cytometry: No monotypic B cell population or aberrant T cell population identified
VDRL reactive 1:1
ACE 1.4 (nl)
Gram stain: 1-10 PMNs/lpf, no PMNs, no organisms
Aerobic culture: no growth
AFB stain: negative
AFB culture: no growth
Fungal culture: no growth

Imaging

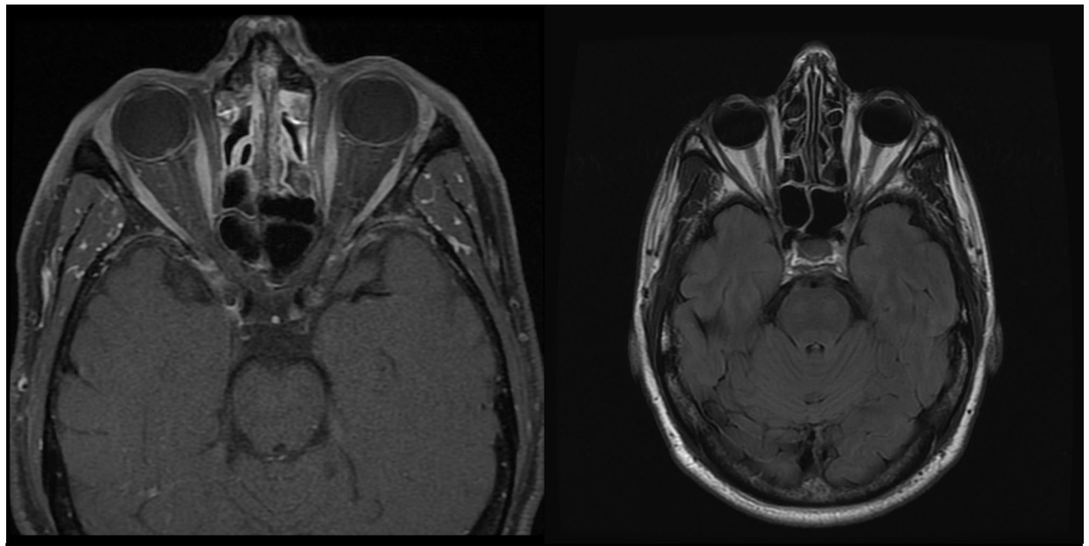

MR Orbit
Axial T1 FS with contrast

MR Head
Axial T2 FLAIR

Examination

Vitals: BP 141/90, HR 93
General: Well-appearing, no oral lesions, normal cardiac exam, lungs with mild expiratory wheezing, skin with faint **rash on upper extremities and chest**
Mental status: Normal
Cranial nerves: Visual acuity 20/20 OU, fundoscopic exam with **right optic disc swelling**, normal on left, pupils were 1.5 to 1 mm bilaterally, no APD, visual fields full, versions conjugate, facial sensation and musculature intact, palatal elevation symmetric, tongue midline
Motor: Normal. **Subtle right pronator drift**. Mild postural tremor.
Sensory: Normal.
Coordination: No ataxia.
Reflexes: 2+ throughout except difficult to elicit at the right knee (history of Osgood-Schlatter), downgoing toes bilaterally.
Gait: Normal.

Conclusions

He was treated with intravenous penicillin G 24 million units continuously for 14 days with resolution of headaches and transient visual obscurations, and improvement in right-sided optic disc edema.

Neurosyphilis should be considered in the differential diagnosis of unilateral papilledema.

References

Castro R, Prieto ES, da Luz Martins Pereira F. Nontreponemal tests in the diagnosis of neurosyphilis: an evaluation of the Venereal Disease Research Laboratory (VDRL) and the Rapid Plasma Reagin (RPR) tests). J Clin Lab Anal. 2008 July;22(4):257-61.
CDC. Primary and Secondary Syphilis – United States, 2005-2013. 2014 May;63(18):402-6.
Chao JR et al. Syphils: Reemergence of an Old Adversary. Ophthalmology. 2006 Nov;113(11)2074-9.
Ho EL, Lukehart SA. Syphilis: using modern approaches to understand an old disease. J Clin Invest. 2011;121:4584-92.
Marra C. Neurosyphilis. UpToDate. 2014 Aug.
Smith JL, Byrne SF, Cambron CR. Syphiloma/gumma of the optic nerve and human immunodeficiency virus seropositivity. J Clin Neuroophthalmol. 1990 Sep;10(3):175-84.
Ritchie MA, Perdigao JA. Neurosyphilis: Considerations for a psychiatrist. Psychiatry Online. 1998.