A case of progressive arm pain

Thomas Mattingly, MD, MSc

Cerebrovascular/Endovascular Neurosurgery

Dept of Neurosurgery

University of Rochester

MEDICINE *of* THE HIGHEST ORDER

UR MEDICINE

32y/o F

Referred from Pain Management

Neck pain radiating down arms R>L, with R hand numbness constant

Electrical sensation if she looks up

Feels clumsy

Worsening over 8 months, especially after a fall

Had tried steroids, NSAIDS, muscle relaxants, PT – no relief

Physical Exam

Gen: BMI 37 kg/m^2

Neck: ROM limited by pain radiating into UEs

Str: 5/5 UE/LE but fine motor coordination slow

Sens: no hyperalgesia or dysesthesia in the fingers

DTR: hyperreflexic throughout

Gait: tandem walk ok

Based on this MRI, what are your options?

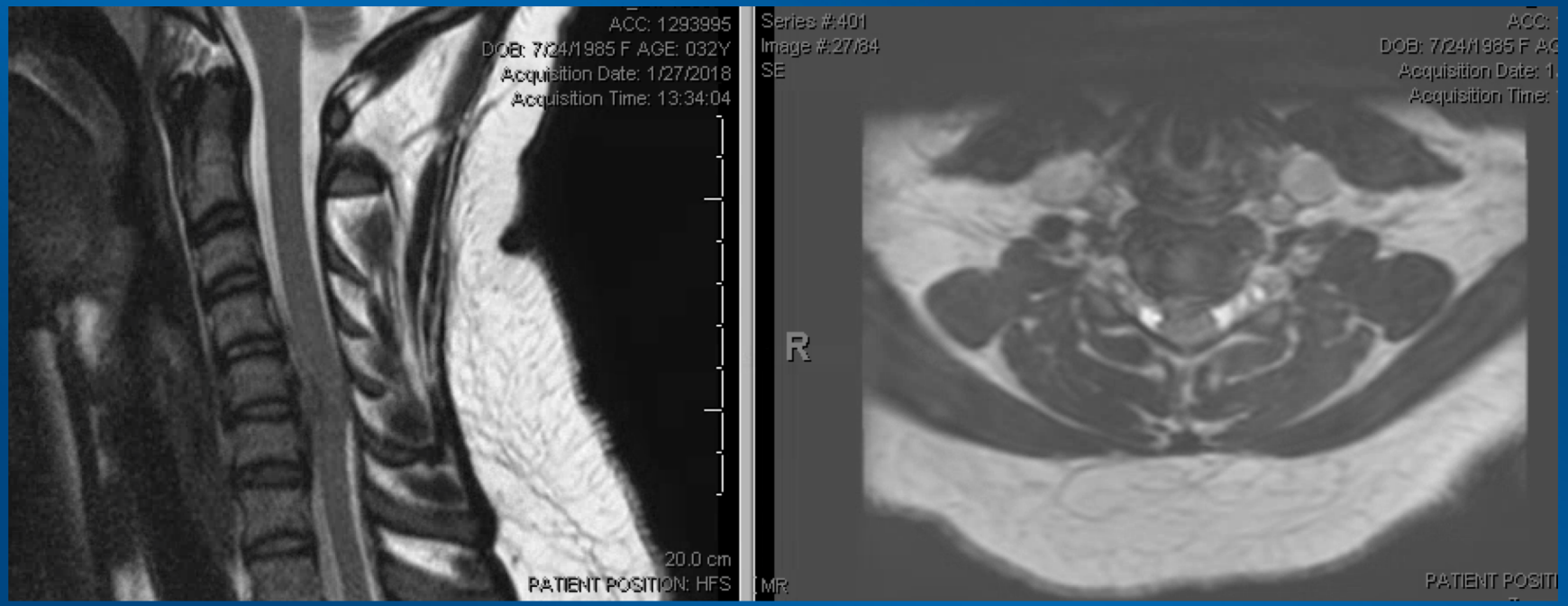

Final result

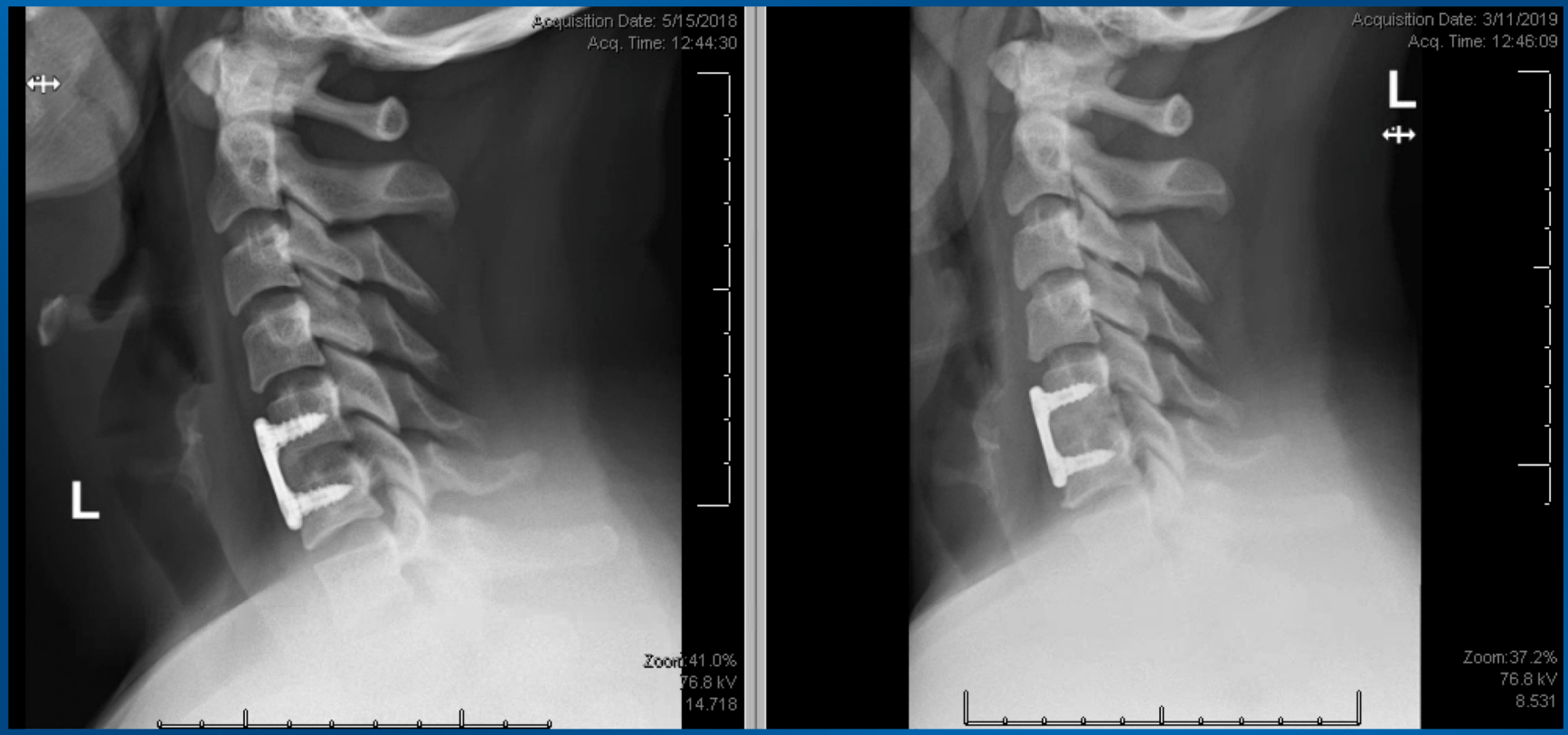

Clinical f/u

D/C on POD 1

At 2 weeks: R hand sensation changed, not normal but different

At 6 weeks: Hand sensation much improved

- Str 5/5 B UE
- Gait normal
- Voice normal
- Neck stiffness without Lhermittes'

At 1 year: Bilateral arm symptoms resolved, neck painless but stiff

- L hand with numbness/tingling in median nerve distribution
- EMG confirmed mild CTS which improved with splinting

UR MEDICINE

MEDICINE *of* THE HIGHEST ORDER