

Keys to Successful Cardioversion

Introduction

Cardioversion is the most direct treatment for atrial fibrillation. However, the success of a cardioversion can be enhanced with careful attention to details, such as electrode placement and skin preparation. Success rates vary among different types of patients and among institutions, and this technical note summarizes the keys to enhance cardioversion success as shared by electrophysiologists and cardiologists with vast experience. Cardioversions, which are intended to terminate atrial arrhythmias, require different electrode placement and preparation than for defibrillation to terminate arrhythmias originating in the ventricle.

Electrode Placement

Cardioversion electrodes can be placed either Anterior-Posterior (AP) or Anterior-Anterior (AA), though AP placement is preferable for maximum current flow through the atria.

AP Placement

The anterior pad should be placed so that the **active area** of the electrode is placed immediately adjacent and right lateral to the sternum, with the outer electrode foam circumference under the clavicle and the **midline** of the electrode located at the **fourth** intracostal space as shown below (the active area of the electrodes is the tin on a solid gel electrode and the foam on a wet gel electrode).

The posterior electrode should be placed as shown, with the left upper corner of the active area sub-scapular and the edge of the active area immediately left lateral to the spine. The center of the electrode should be placed at the level of the T7 vertebra. Current flow in this position is shown in (Figure 3).

In AA placement (Figure 4) the sternal pad should be placed in the same position or slightly higher than for AP placement, though still below the clavicle. The center of the active area of the Apex pad should be placed in the midaxillary line at the level of the 5th intracostal space.

Figure 1

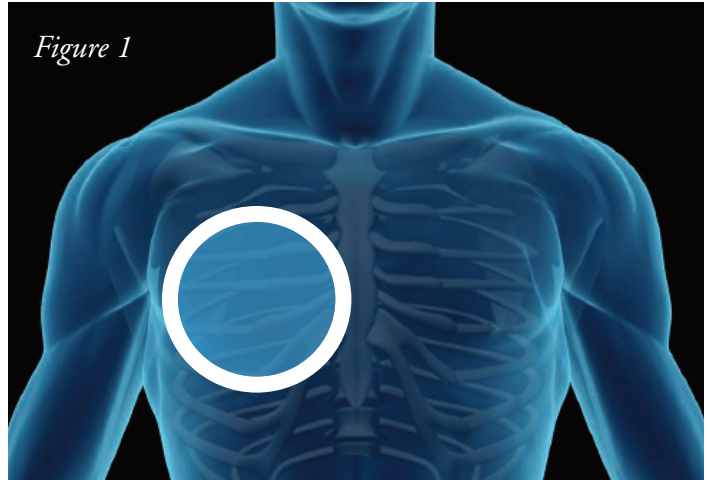


Figure 2

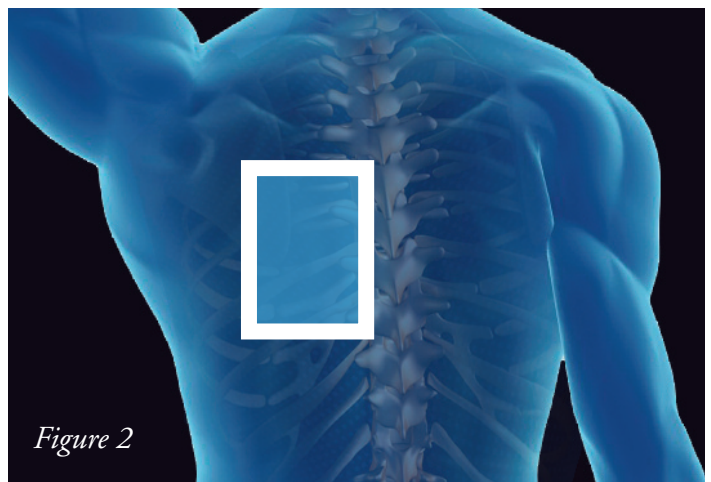
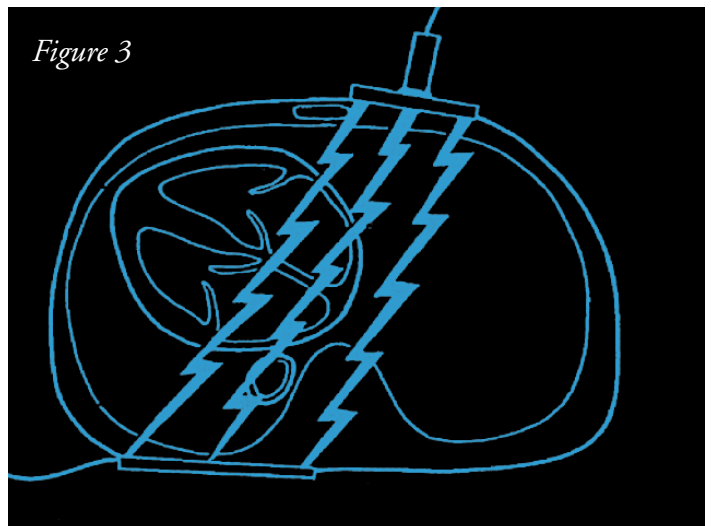


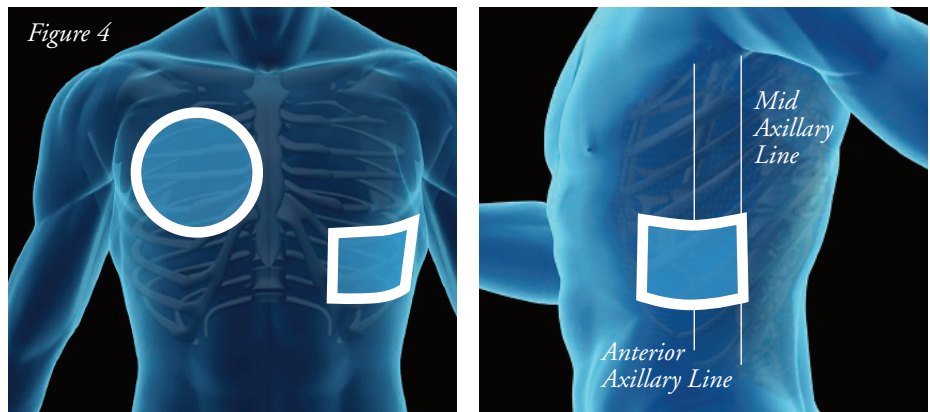
Figure 3



Tips for Successful Cardioversion

Thanks to Mark Niebauer, M.D. from the Cleveland Clinic here's a short list of things you can do to improve the likelihood of cardioversion success.

- Use the A-P position to maximize current flow through the atria.
- Consider wet gel electrodes over solid gel for optimal coupling of skin and gel.
- Pay careful attention to skin preparation; make sure the surface is dry, free of hair and lotions that can impact adhesion.
- Apply pads carefully. Place the posterior pad first, and carefully roll it onto the skin to ensure good adhesion and no trapped air pockets.
- Make sure that the ECG is syncing on the R Wave; the sync function can sometimes lock onto high amplitude T Waves when present.
- If more than one shock is required, allow the ACC recommended 1 minute rest time between shocks. Be patient.
- Patients with certain medications, such as beta blockers may be at risk for post shock bradycardia; transcutaneous pacing may be required until they stabilize. Another advantage of A-P placement is that pacing can be initiated immediately by moving the sternal pad to the left side.



Shock Protocols:

Smaller patients with recent onset A-Fib generally will convert easily on the first shock. In this group Dr. Niebauer recommends a low dose of 75 Joules biphasic for maximum myocardial protection and a high first shock efficacy.

In routine patients with persistent A-Fib, a starting dose of 100 – 120 Joules biphasic generally will result in > 90% first shock success according to Dr. Niebauer.

Patients who are known to be or who are suspected to be difficult to cardiovert may benefit from starting with the maximum dose of 200 joules biphasic. In these patients exerting pressure on the pads during the shock shortens the distance between the pads for optimal current flow. Dr. Niebauer also advises that one should not hesitate to move the pads around if the initial shock is unsuccessful; it may even be necessary to move the sternal pad to the opposite side of the sternum in some patients.

References

ACC/AHA/ESC 2006 Guidelines for the Management of Patients with Atrial Fibrillation. *Circulation* 2006;114:700-752.

Lown, B. et al. "Cardioversion" of atrial fibrillation. *New England Journal of Medicine* 1963;269:325-331.

Field, J.M., Hazinski, M.F., & Gilmore, D. [Eds]. *2006 Handbook of Emergency Cardiovascular Care for Healthcare Providers*. American Heart Association.

Neal, S., Ngarmukos, T., Lessard, D. & Rosenthal, L. Comparison of the efficacy and safety of two biphasic defibrillator waveforms for the conversion of atrial fibrillation to sinus rhythm. *American Journal of Cardiology* 2003;92:810-814.

Mittal, S Ayati, S et al. Transthoracic Cardioversion of Atrial Fibrillation. Comparison of Rectilinear Biphasic Versus Damped Sine Wave Monophasic Shocks. *Circulation*. 2000;101:1282-1287.

Niebauer M et al. Comparison of the rectilinear biphasic waveform with the damped sine monophasic waveform for external cardioversion of atrial fibrillation and flutter. *Am J Card*. 2004: Vol. 93. 1495-99.

Sado, D.M. et al. Comparison of the effects of removal of chest hair with not doing so before external defibrillation on transthoracic impedance. *American Journal of Cardiology* 2004;93:98-100.

Sirna, S.J. et al. Factors affecting transthoracic impedance during electrical cardioversion. *American Journal of Cardiology* 1988;62:1048-1052.

Kirchhof, P. et al. Anterior-posterior versus anterior-lateral electrode positions for external cardioversion of atrial fibrillation: A randomized trial. *Lancet* 2002;360:1275-1279.

Sirna, S.J. et al. Factors affecting transthoracic impedance during electrical cardioversion. *American Journal of Cardiology* 1988;62:1048-1052.

Mehdirad AA et al. Improved Clinical Efficacy of External Cardioversion by Fluoroscopic Electrode Positioning and Comparison to Internal Cardioversion in Patients with Atrial Fibrillation. *PACE* 1999; Vol. 22 Issue 1,-237.