

## What is Ankylosing spondylitis?

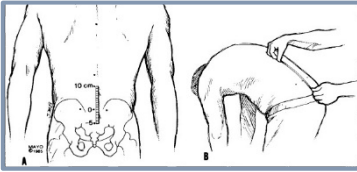
- Ankylosing spondylitis (AS) is a complex, immune-mediated disease characterized by lower back pain, stiffness and fatigue
- AS start prior to age 4 year in 90-95% of those affected
- Patients with AS have axial and enthesal inflammation, new bone formation and spinal fusion
- Extra articular manifestations are common and include psoriasis, anterior uveitis and inflammatory bowel disease
- Diagnosis is often delayed by up to 10 years

## What are the most common symptoms of AS?

- **Inflammatory back pain** – (if 4 of 5 are present)
  - Onset of symptoms prior to age 40 years
  - Insidious onset (and present for more than 3 months)
  - Improves with physical activity/ exercises
  - No improvement with rest
  - Pain at night/ early mornings
- **Peripheral enthesitis** (seen in one third of patients)
  - Achilles tendonitis, plantar fasciitis, tenderness over tibial tuberosity
- **Peripheral arthritis**
  - May be asymmetric
  - Can involve hips, shoulders, costo-sternal and costo-vertebral joints

## What are the most common signs of AS?

- **Limited flexion of lumbar spine**- Schober/ modified Schober test (see image)
- **Sacroilitis** – positive Patrick's or Faber test (see image)
- **Chest expansion** - decreased in severe, long standing disease
- **Synovitis, enthesitis or dactylitis** – may be seen in peripheral joints
  
- Psoriasis – seen in about 9%
- Uveitis - seen in up to 25%



Schober test: Image from Mayo Clinic Proceedings

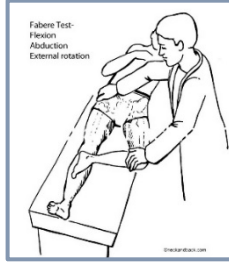
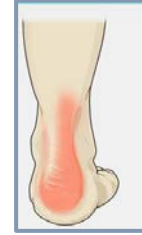

Image from Dr. Donald Corenman-Colorado spine doctor; www.neckandback.com



Enthesitis – image from alamy.com

## Who is at risk for AS?

- No one is sure what causes AS
- Genetic risk factors play a role - HLA B27 antigen is most important.
- Commonly begins between age 20 and 30 years
- Men are twice as likely as women to have AS

## Diagnostic criteria for AS

Sacroilitis on imaging  
plus  
≥ 1 Spondyloarthropathy (SpA) features

### SpA features

- Inflammatory back pain
- Arthritis, Enthesitis, Dactylitis
- Uveitis
- Psoriasis
- Crohn's / colitis
- Good response to NSAIDs
- Family history of SpA
- HLA B27
- Elevated CRP

HLA-B27  
plus  
≥ 2 other SpA features

### Sacroilitis on imaging

- Active (acute) inflammation on MRI suggestive for of sacroilitis associated with SpA
- Definite radiographic sacroilitis according to modified New York criteria

### Contact information for the URM C Rheumatology clinic



Phone number: 585 486-0901

Fax number: 585 340-5399

